

# Laboratory Evaluation of a novel technique for myopia correction: Continuous wave laser cornea shrinkage coupled with CXL.

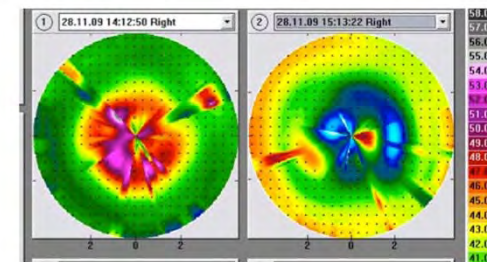
A. John Kanellopoulos, MD

Professor NYU Medical School, NY

Director, Laservision.gr Institute, Athens, Greece

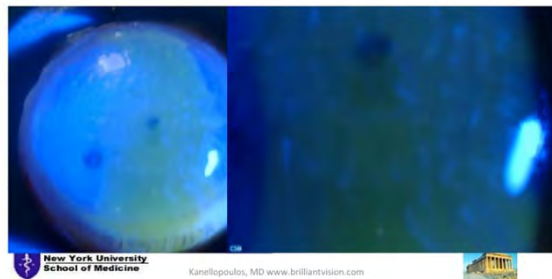
**Financial Interests: None**

Flattening of cornea


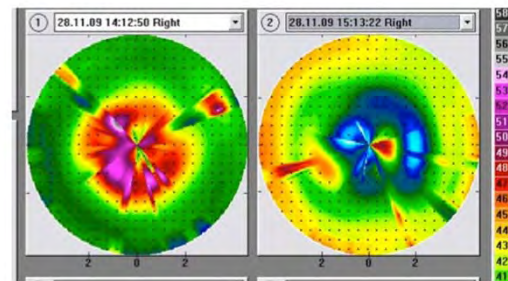


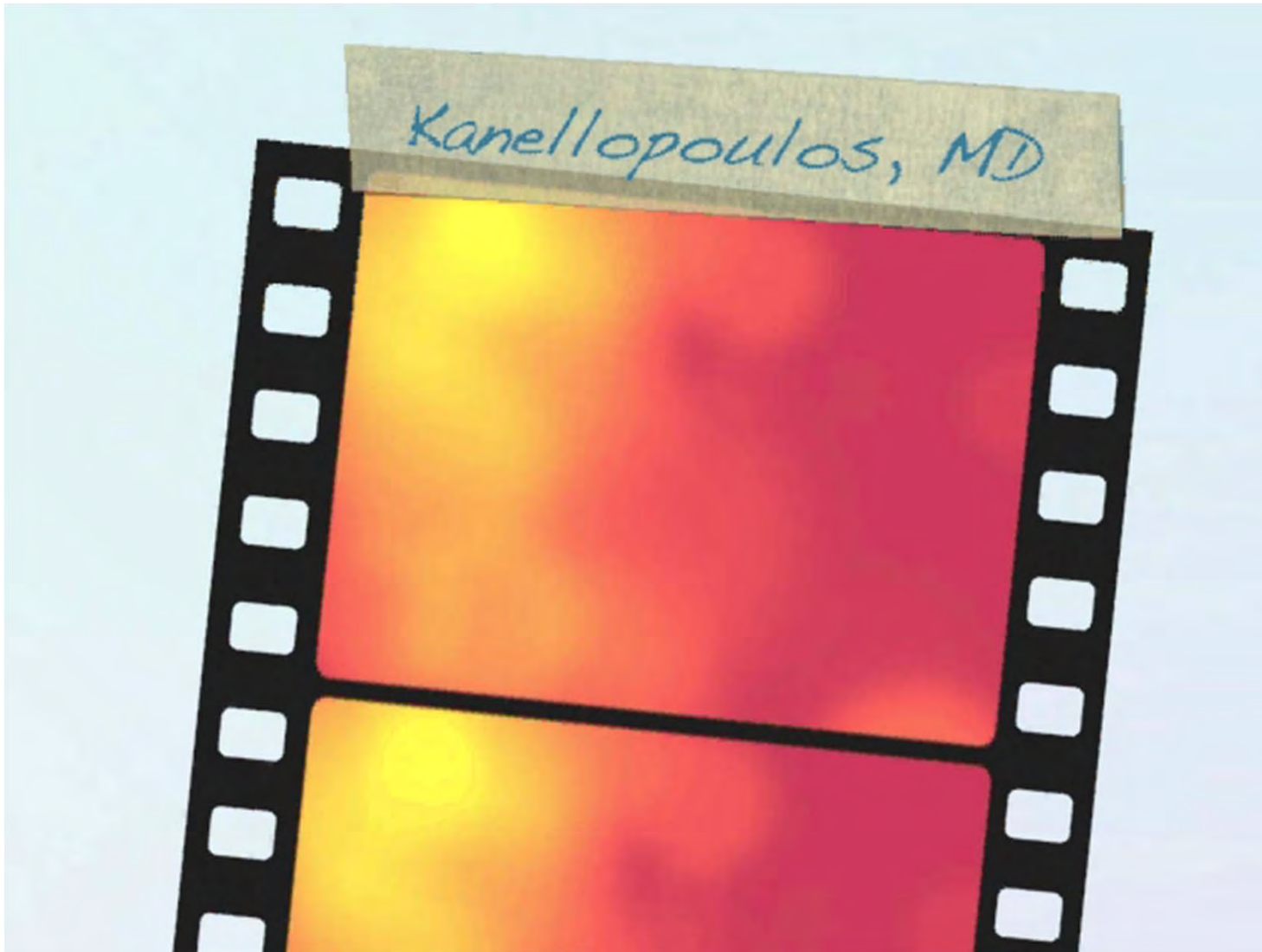
**Methods:** 12 cadaver corneas were evaluated with pre- and post-operatively with fluorescein dye staining, biomicroscopy, placido disc topography, Pentacam tomography and cornea OCT. Utilizing a cooled sapphire applanation disc 3 concentric ring-like intrastromal shrinkage treatments were applied with a continuous wave laser. CXL was then performed with the epithelium on, using 0.1% riboflavin solution and 10mw/cm<sup>2</sup> UV irradiation.

No epithelial defect



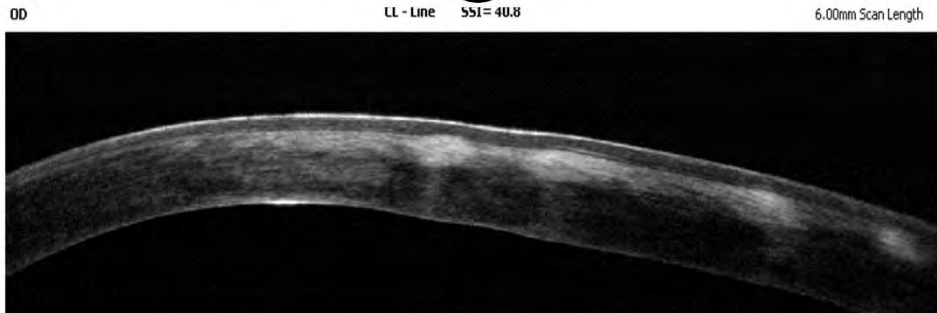Flattening of cornea



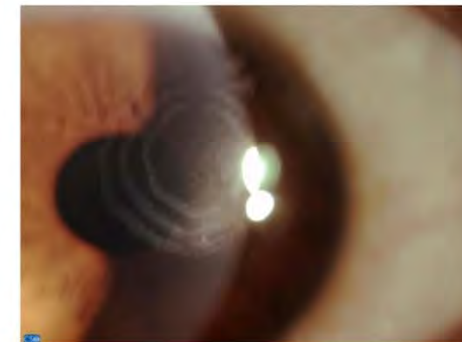
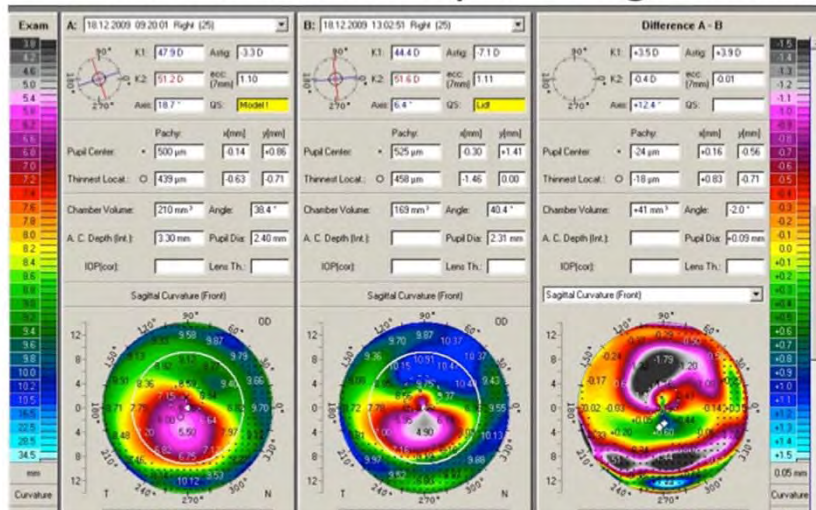


# Cornea OCT changes

10 minutes postop



8 months follow-up-no regression!

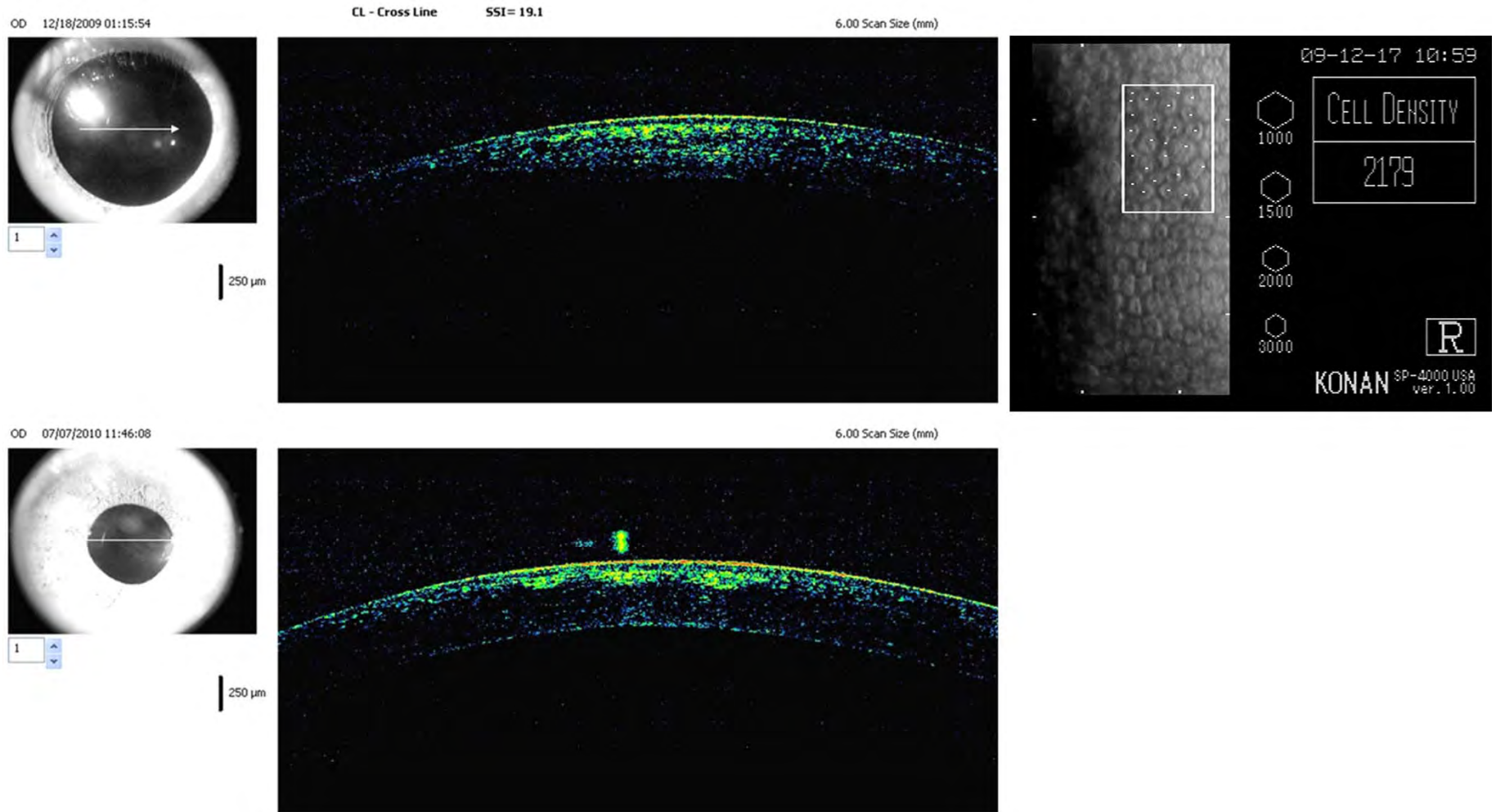


8 months follow-up  
No regression of the flattening effect!





# OCT images pre-post 8 mos



**Results:** The laser treatment was noted by mid-stroma whitening, but no epithelial defect. Both topography measurements documented significant uniform cornea flattening of 4-8 diopters in a central round zone of 5 mm. cOCT documented stroma hyperefectivity 50 to 350 microns depth.

**Conclusions:** This novel, minimally invasive laser and CXL technique may provide an alternative for myopic cornea correction without tissue removal. Further studies are required to validate the efficacy and long term stability of these findings.

