

Novel Cornea OCT (cOCT) findings in early and long term follow up of collagen cross-linking (CXL) for keratoconus (KCN)

A. John Kanellopoulos, MD
Associate Professor of Ophthalmology,
NYU Medical School, NY, NY, USA
Director, Laservision.gr Institute, Athens, Greece

Financial Disclosures

- none

Introduction

- The depth and degree of collagen cross-linking has been difficult to evaluate in clinical reality. By scanning some of these corneas with cOCT we encountered different findings than non-cxled corneas. We are therefore herein attempting to evaluate these novel, reproducible cornea OCT findings the first 6 months and at least 3 years following CXL (collagen cross-linking) for keratoconus

Methods

We evaluated a total of 125 KCN cases from our clinical practice; 70 recent (group A) and 55 treated earlier (group B) were evaluated for the presence and stromal depth of intrastromal CXL lines (I-CXL-I), cornea thickness in microns (CT), UCVA, BSCVA, keratometry (K), topography, endothelium (ECC) and clarity.

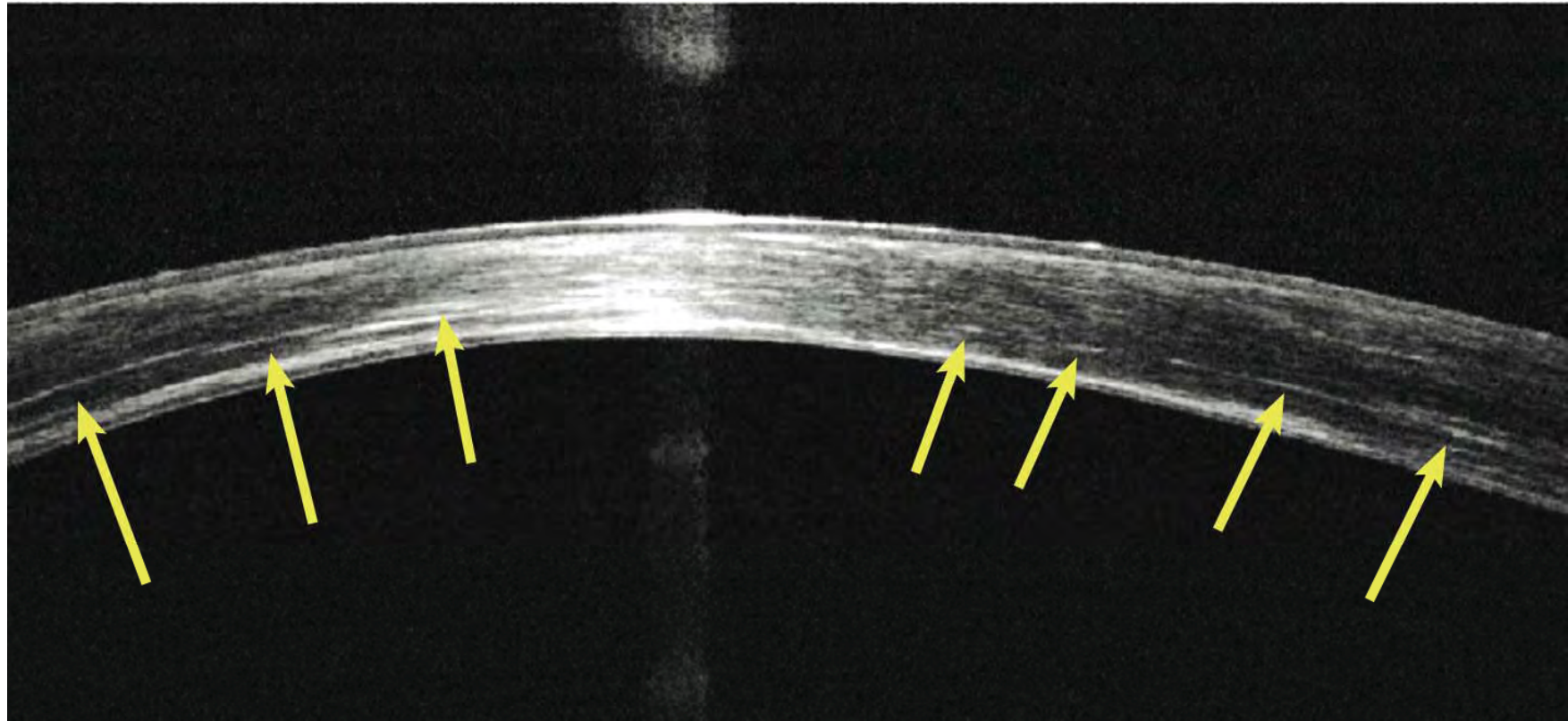
The Optovue OCT device was used in this study

Results

68 of Group A and 51 of group B cases demonstrated I-CXL-I.

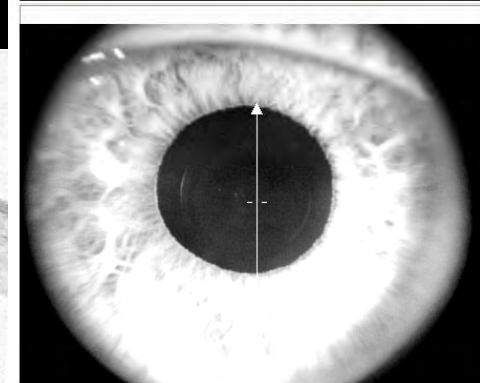
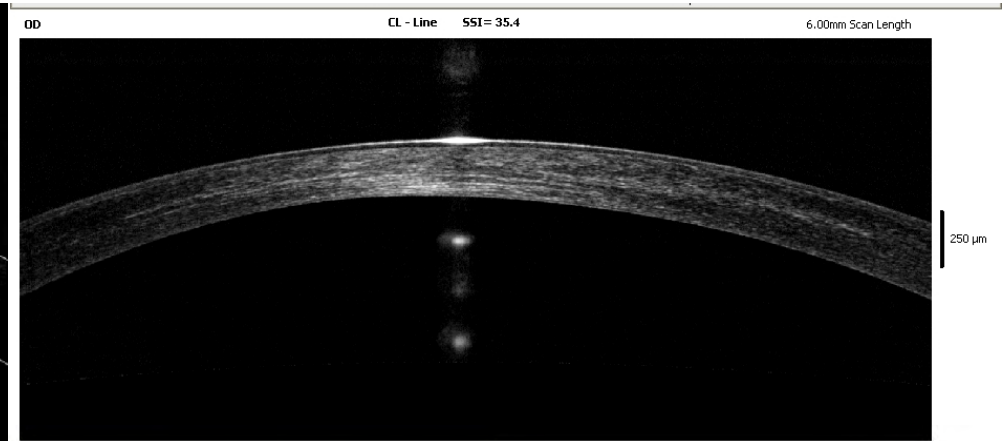
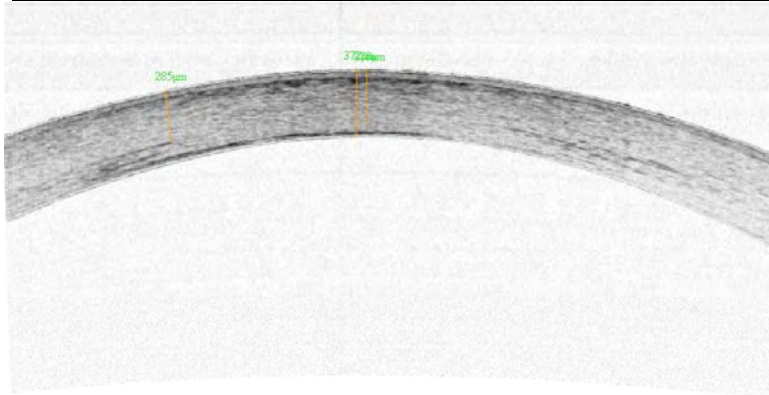
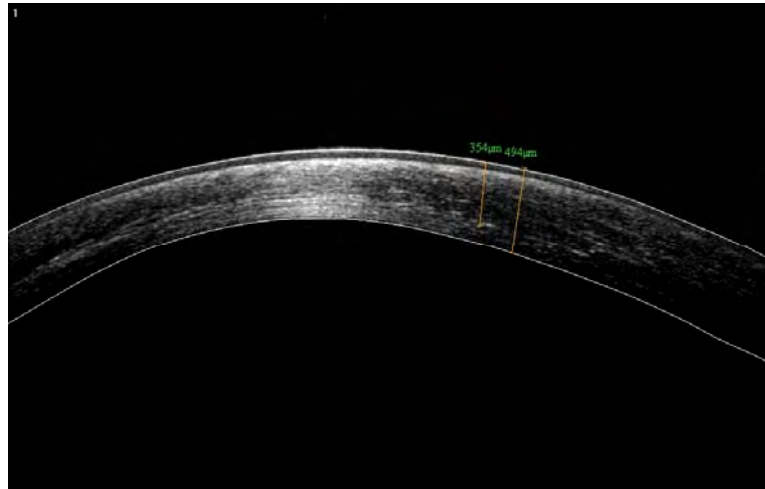
The mean values for group A and group B were respectively: CT : 370, 380, I-CXL-I depth: 255, 262, UCVA: 20/60, 20/50, BSCVA: 20/40, 20/30, K: 49.5, 48.5, ECC: 2550, 2600.

Mean follow-up: 7 , 38 months respectively



A cornea OCT demonstrating hyper-reflective intra-corneal stromal “lines” at 2/3 depth (yellow arrows) corresponding with the clinical presence of CXL demarcation line in a patient, 3 years following the combined Topography guided-PRK/ and CXL procedure.

Other examples



of Averages:13

Average

No Average

Diagnosis:

Report Date: Monday December 01 04:00:26 2008

Conclusions

cOCT appears to demonstrate reproducible early and long-term CXL cornea findings.

The hyper-reflective “lines” may represent induced cornea density or subtle intrastromal cornea scarring

This may constitute a possible novel non-invasive measurement, to evaluate and titrate the amount, extent and depth of intrastromal effects of the CXL treatment in keratoconic and possibly ectasia eyes.