

# Femtosecond laser assisted Lamellar Keratoplasty and Collagen cross-linking in keratoconus management

A. John Kanellopoulos, MD

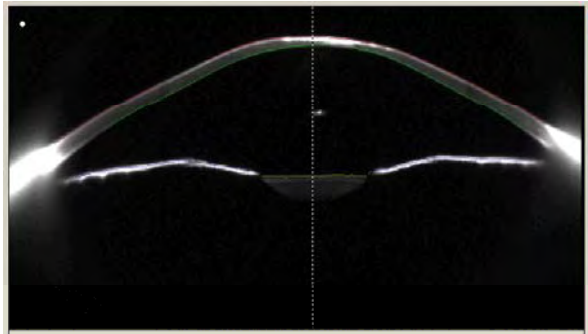
Clinical Associate Professor NYU Medical School, NY

Director, Laservision.gr Institute, Athens, Greece

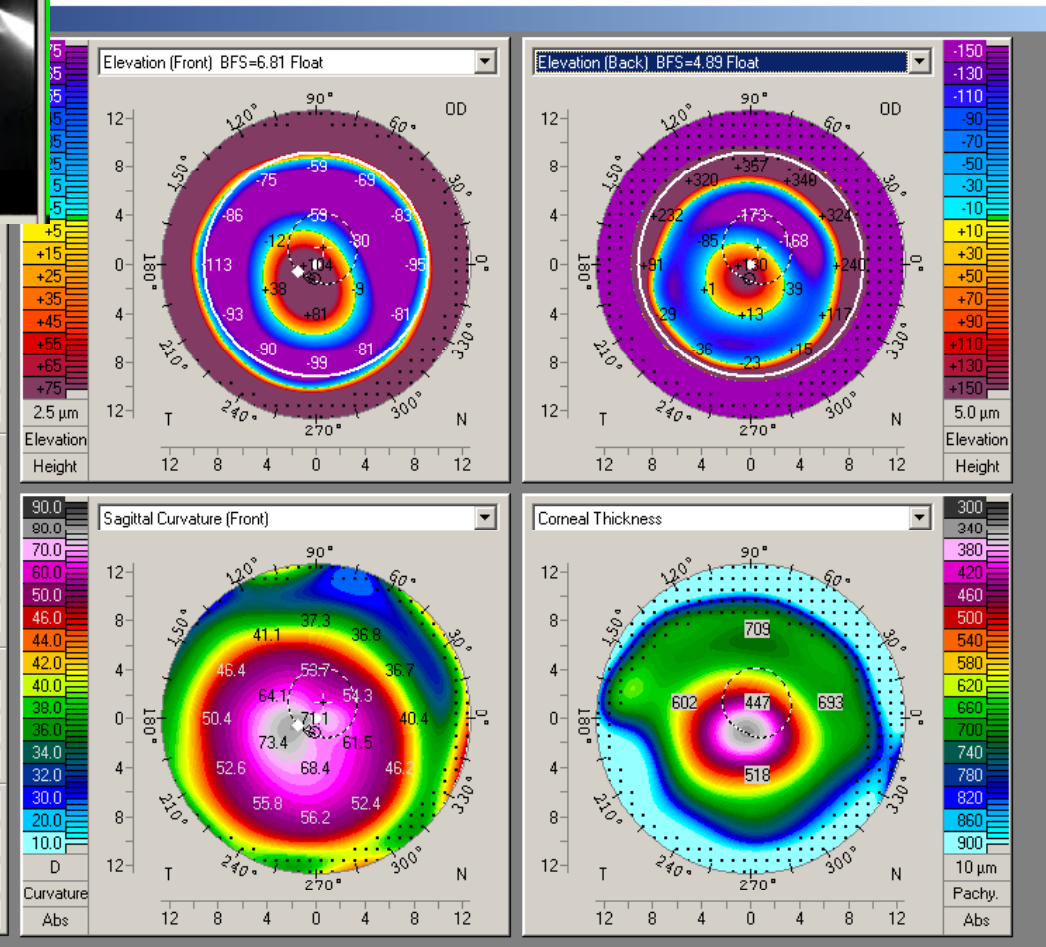
# 18y/o male with advanced KCN PK Vs lamellar keratoplasty

**Dr. A.J. Kanellopoulos, MD**

Associate Professor, NYU Medical School




Cornea Front			
Rh:	4.91mm	K2:	68.8D
Rv:	5.34mm	K1:	63.1D
Rm:	5.13mm	Km:	65.8D
QS:	Data!	Axis:	96.8°
ecc:	1.43	Rper:	7.56mm
(7mm)		Rmin:	4.27mm
Cornea Back			
Rh:	3.56mm	K2:	-11.2D
Rv:	3.59mm	K1:	-11.2D
Rm:	3.57mm	Km:	-11.2D
QS:	Data!	Axis:	38.9°
ecc:	1.71	Rper:	7.02mm
(7mm)		Rmin:	2.70mm
Pachy: x[mm] y[mm]			
Pupil Center:	447µm	+0.29	+0.63
Pachy Apex:	363µm	0.00	0.00
Thinnest Locat.:	341µm	-0.07	-0.56
Cornea Volume: 63.7mm <sup>2</sup> KPD: +5.5D			
Chamb. Volume: 225mm <sup>2</sup> Angle: 35.3°			
ACD (Int.): 4.31mm		Pupil D: 2.62mm	
Enter IOP (Sum): +12.9		Lens T:	

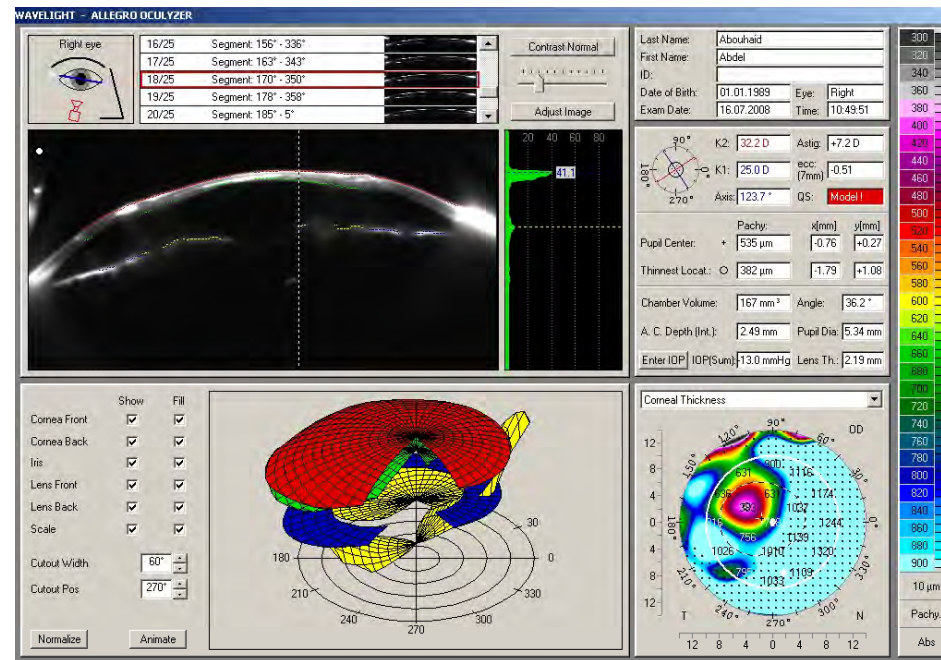
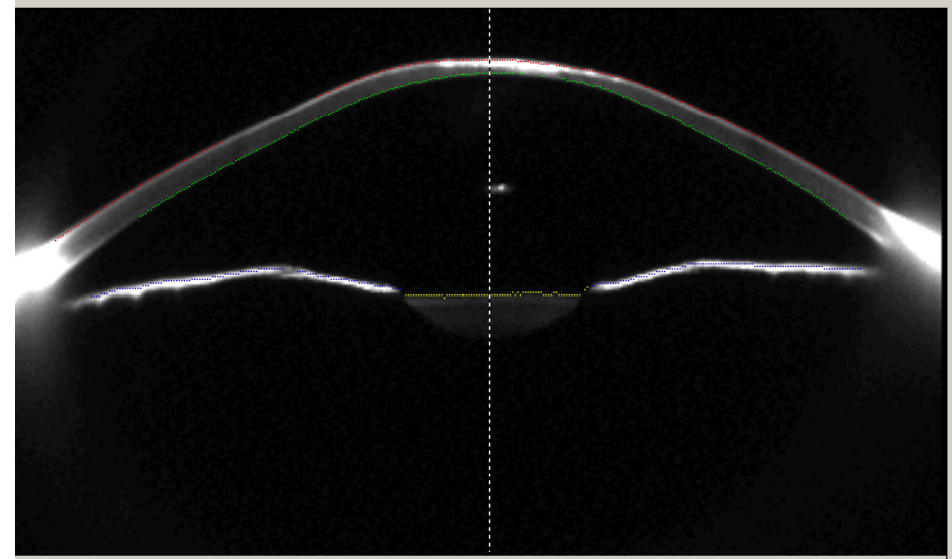
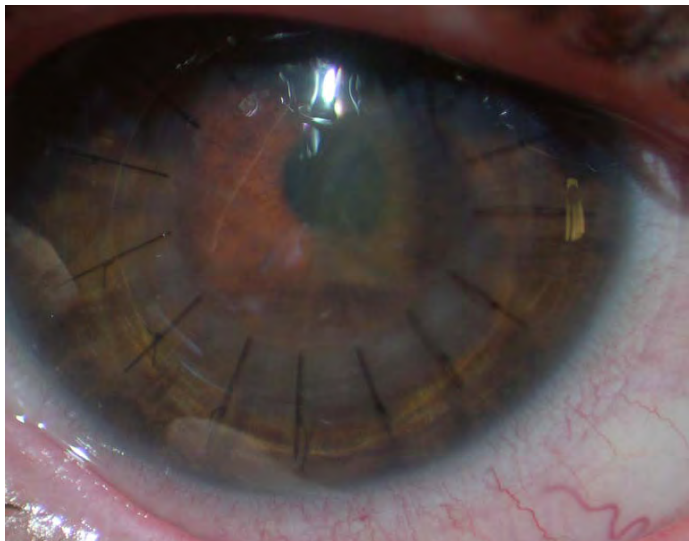
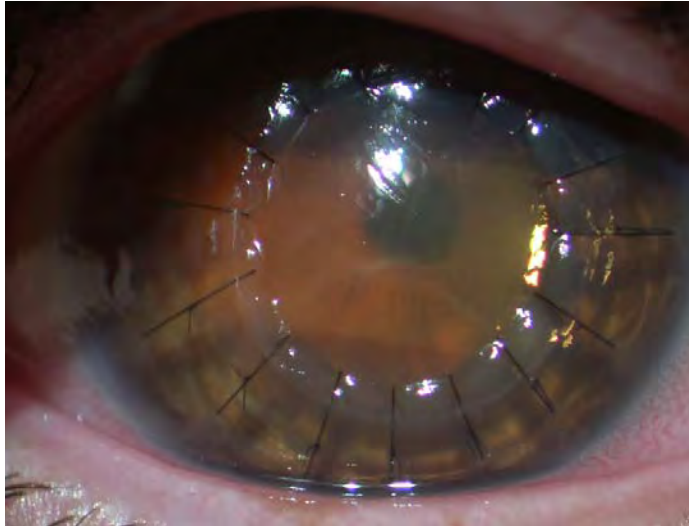


Kanellopoulos MD

# Lamellar graft and CCL after topo-guided normalization of a cone



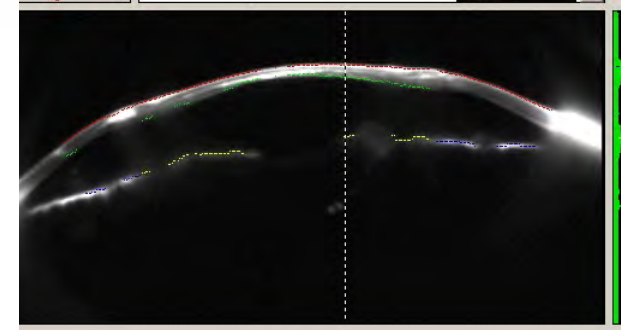
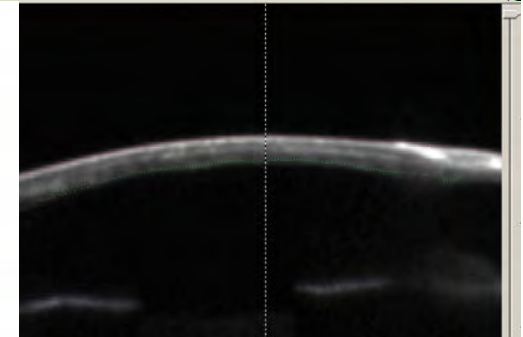
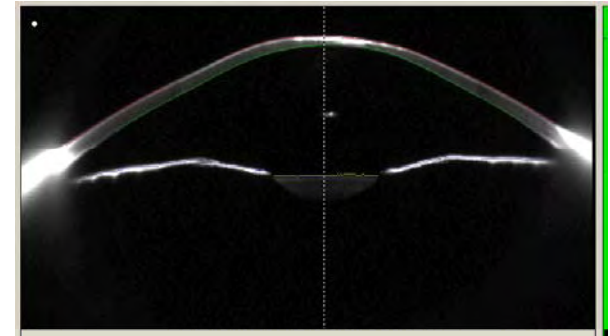
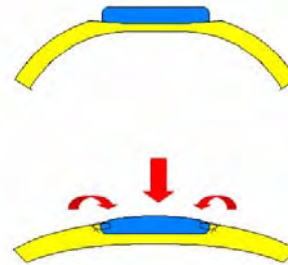
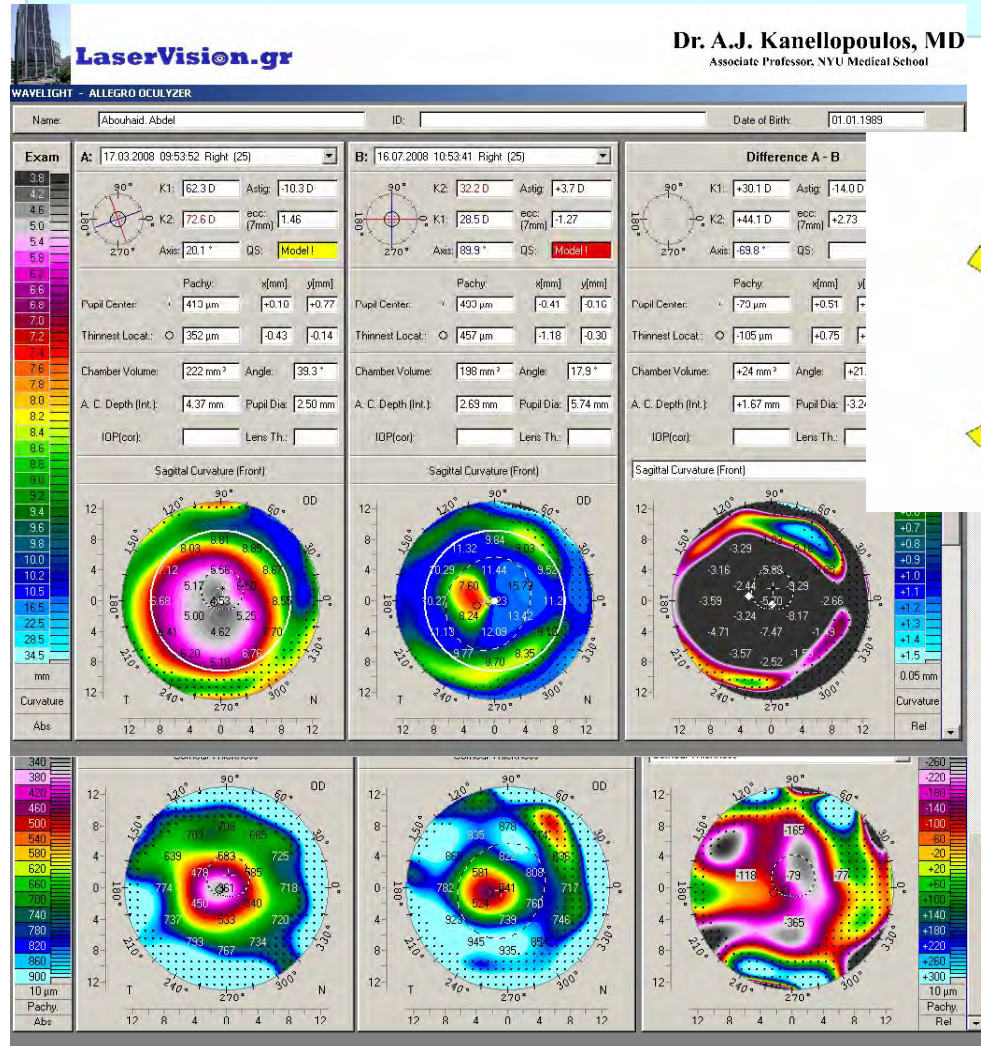
# Pre-post



Kanellopoulos MD



# 6 months UCVA 20/60!



Kanellopoulos MD