

Clinical evaluation of foldable acrylic phakic IOL (fP) implantation ASCRS, San Diego, 2011

**A. John Kanellopoulos, MD
Professor NYU Medical School, NY
Director, Laservision.gr Institute, Athens, Greece**

Financial Interest: Travel Reimbursement from Alcon, Wavelight,
Bausch and Lomb



Introduction

Phakic IOL implantation is a valid option in the correction of high myopia and myopia in cases with thin or irregular cornea.

We have worked with several anterior chamber and posterior chamber phakic IOLs with all advantages and potential disadvantages.

To evaluate the safety, efficacy and clinical parameters of the Cache, phakic IOL in the visual rehabilitation of high myopia (HM).



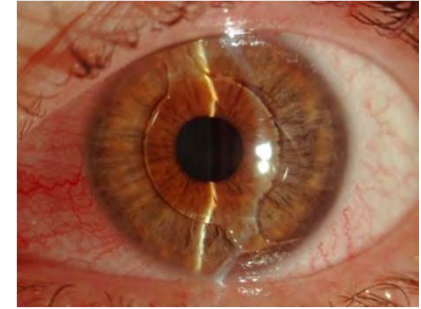
Disadvantages of PC phakic IOLs

- risk for papillary block,
- the need for a peripheral iridectomy,
- cataract formation due to lens injury during the procedure
- glaucoma due to angle obstruction
- Dislocation in the posterior pole
- Pigment dispersion



Methods

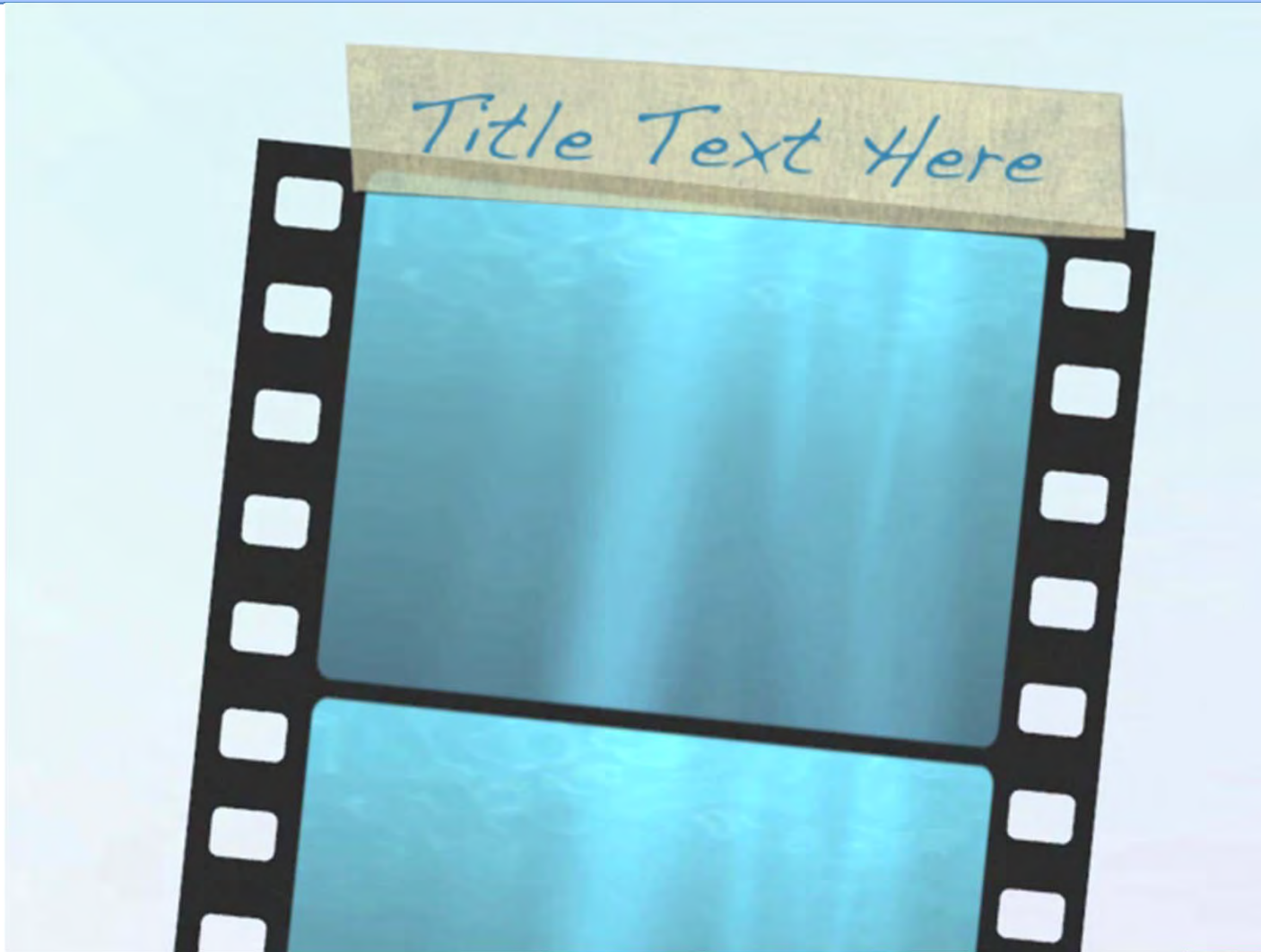- The hydrophobic acrylic material used in the cache phakic IOL has been extensively used in routine cataract surgery implantation with excellent results and biocompatibility. We decided to evaluate the safety, efficacy and clinical parameters of the Cache, phakic IOL (Alcon, Fort Worth, TX) in the visual rehabilitation of high myopia (HM).



We studied 15 eyes of 8 consecutive patients were evaluated pre- and 6 months post- operatively for: age, UCVA, BSCVA, refraction, cylinder (C), topographic cylinder change (TCc), endothelium (ECC and possible complications.



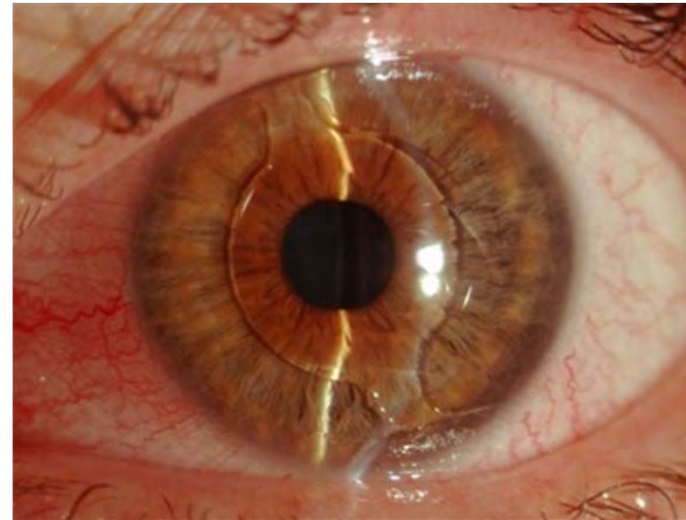
Surgical Technique



Results:

- The mean age was 27 years and mean values pre- and post-op were respectively: UCVA: from 20/400 to 20/25,
- BSCVA: from 20/25 to 20/18, (mag effect)
- Spherical equivalent reduction from 10.2 to 0.5 diopters,
- Cylinder: from -1.75D to -1.25 D, Topographic Cylinder change: -0.35D, Endothelial cell count CC: 2650, 2550.
- No complications were encountered in his small group.

1 day post-op: 20/20



Conclusions:

- This phakic IOL appears to be safe and effective in high myopia.
- Significant advantages include:
- a simple implantation technique,
- the very small incision needed (2.5mm),
- no need for peripheral iridectomy,
- little anterior chamber angle changes from the haptics.

Haptics viewed by gonio



Potential limitations

- AC depth
- Calculation of white to white-potential misfit
- Addressing high astigmatism-toric?
- The lens centers in the AC, not the pupil
- Long term Endothelial cell studies necessary
- Potential risk for retina complications needs to be assessed by larger studies





This study suggests highly reproducible flap parameters with both platforms. Further clinical studies may validate these data.

Thank you
www.brilliantvision.com

