

Evaluation of femtosecond laser-assisted combined Descemet's stripping automated endothelial keratoplasty (DSAEK) and astigmatic keratotomy (AK) surgery



Kathy M. Tran¹, Silas L. Wang, M.D.¹, Ioanna Kontari, M.D.², George Asimellis, Ph.D.², and A. John Kanellopoulos, M.D.^{1,2}

kathy.tran@nyumc.org

silas.wang@nyumc.org

jkontari@gmail.com

asimellis@laservision.gr

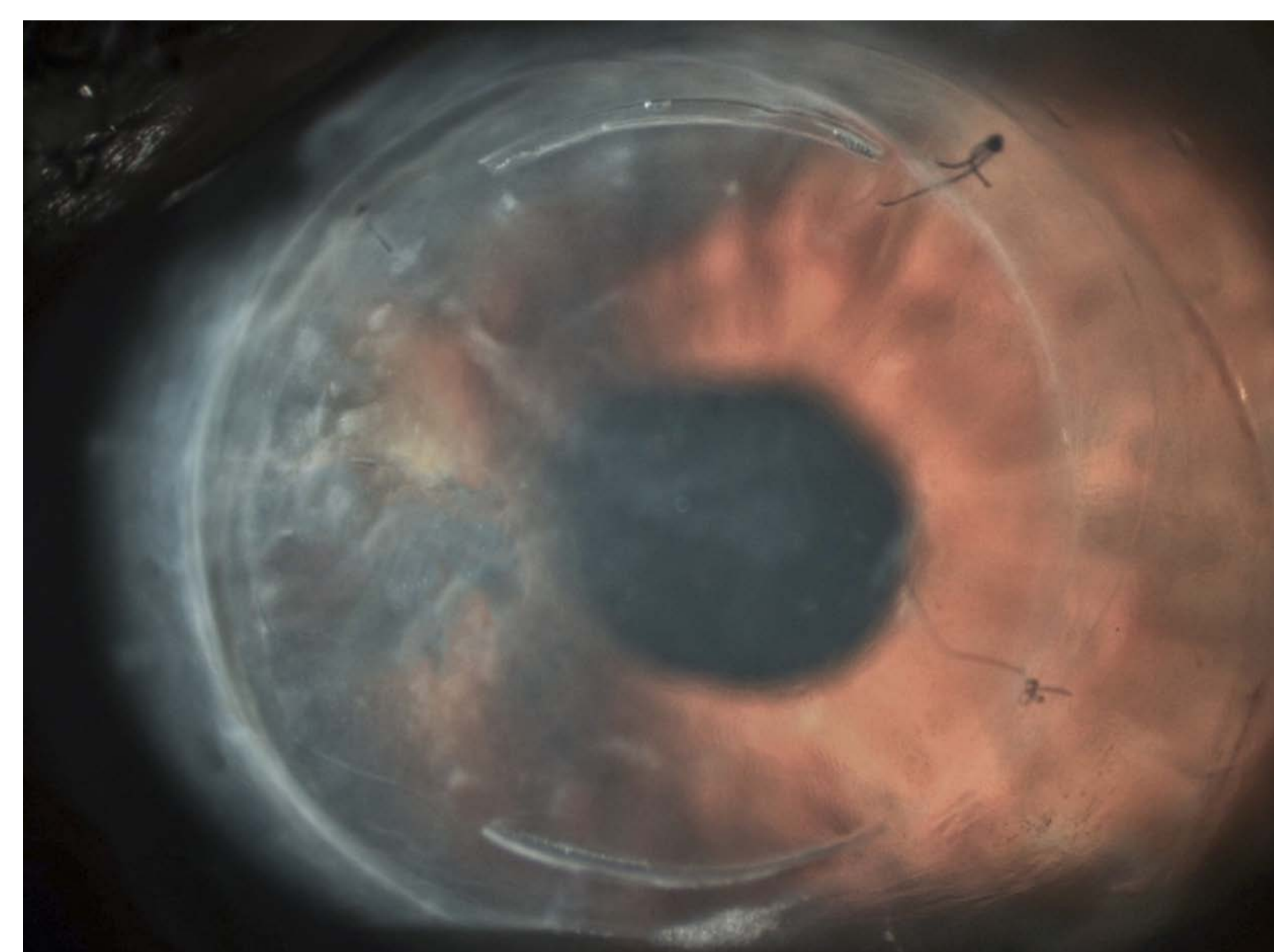
ajkmd@mac.com

¹Department of Ophthalmology, New York University School of Medicine, New York, New York

²Laservision.gr Institute, Athens, Greece

Purpose: To evaluate the safety, efficacy, and clinical parameters in combined clear cornea DSAEK and AK surgery performed with the LenSx femtosecond laser (Alcon, Fort Worth, TX).

Background: Femtosecond laser systems are being used for increasingly numerous applications during ocular surgery. Among these applications are the creation of clear corneal incisions for intraocular surgery as well as the creation of AK segments for the correction of astigmatism. Compared with manual blade techniques, femtosecond laser-assisted incisions have several potential advantages. The placement, size, and depth can be made more accurately and uniformly, and are less dependent on surgeon technique. AK incisions can be left partially closed for postoperative adjustment, or can be made entirely intrastromally.



Illustrative case

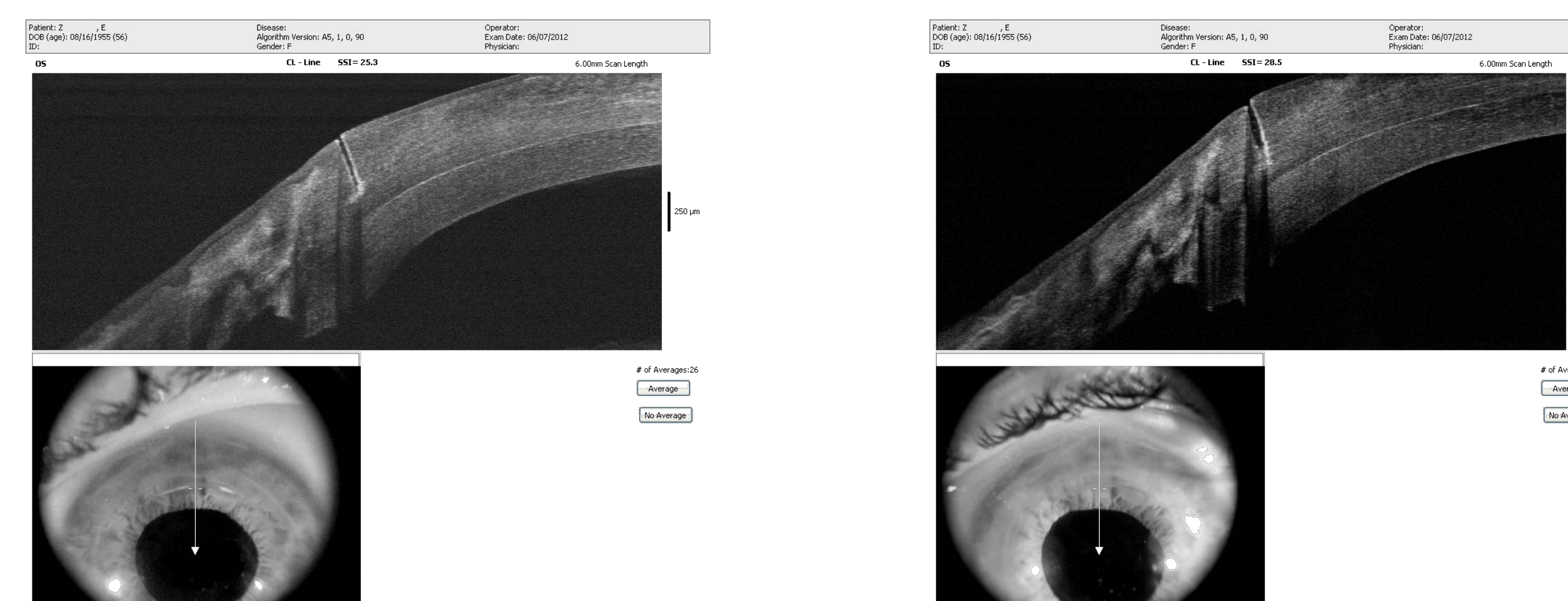
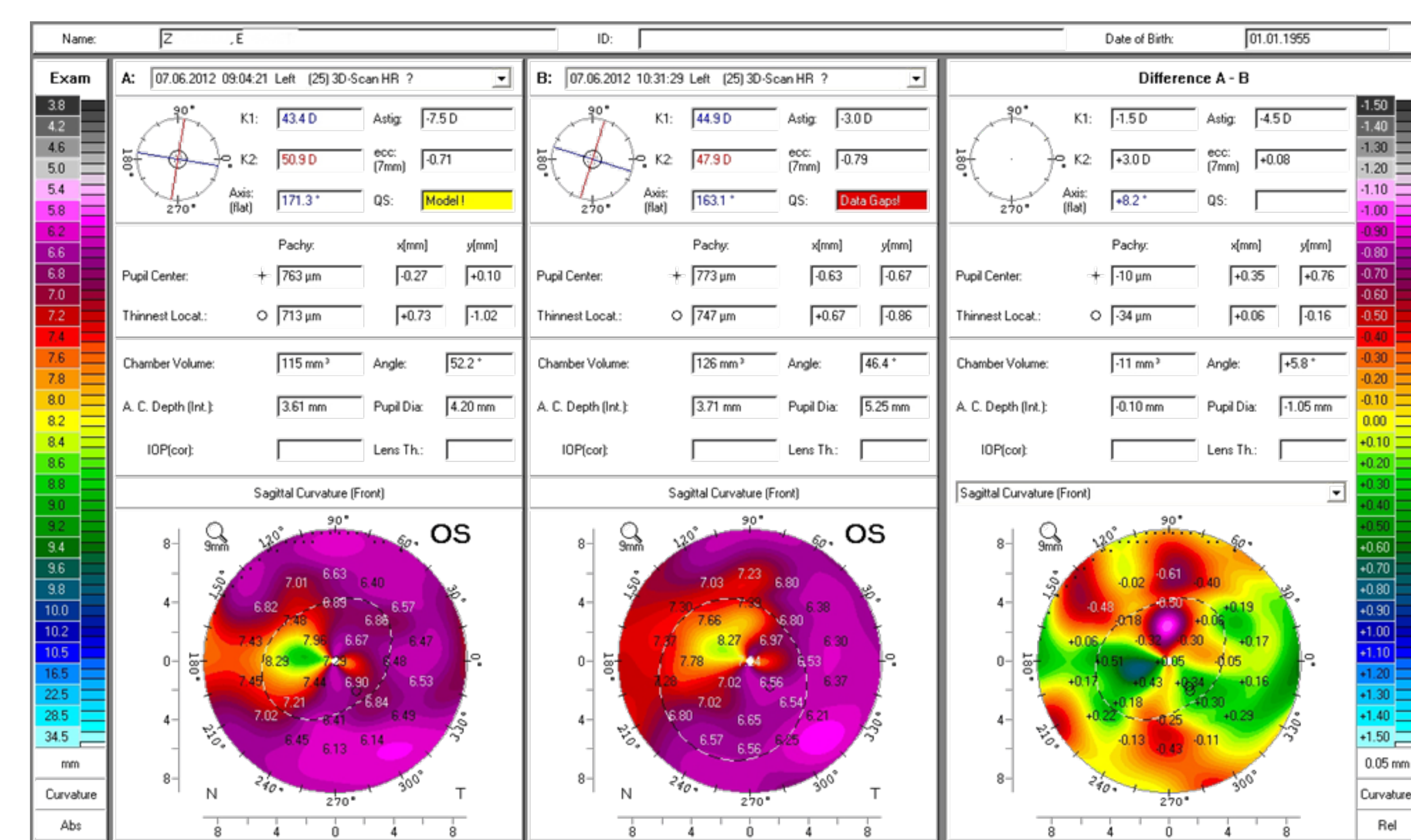
57 yo female, s/p PK os x 2

Underwent DSAEK and AK with LenSx

Pre-op UDVA: 0.5- (20/40-)

CDVA with +0.50 -1.00 x 180: 0.5+ (20/40+)

Post-op UDVA: 0.7 (20/30)



Methods: 15 eyes of 13 consecutive patients who underwent combined DSAEK and AK were evaluated pre-operatively and 6 months post-operatively for: age, uncorrected distance visual acuity (UDVA), corrected distance visual acuity (CDVA), refraction, cylinder (C), topographic cylinder change (TCc), endothelial cell count (ECC), and possible complications. The 3 host cornea incisions of 3.5 mm, 1.2 mm, and 1.2 mm, along with 2 partial thickness arcuate incisions at the 6 mm optical zone, were performed by the laser. The arcuate incisions were adjusted manually at the slit lamp at 3 months.

Results: The mean age was 68 years and mean values pre-operatively and post-operatively were respectively: UDVA: 20/400 and 20/40, CDVA: 20/100 and 20/25, C: -2.25 D and -0.55 D. The mean TCc was -2.45D. No complications were experienced during the follow-up period.

Conclusions: This novel bladeless femtosecond laser-assisted clear cornea combined DSAEK and AK surgery appears to be safe and effective in facilitating reproducible wound creation and corneal astigmatic reduction.

Commercial Relationship Disclosure:

Kathy Tran: No Commercial Relationship
 Silas Wang: No Commercial Relationship
 George Asimellis: No Commercial Relationship
 Ioanna Kontari: No Commercial Relationship
 A. John Kanellopoulos: Alcon Laboratories, Inc.: Consultant; Avedro: Consultant; Bausch and Lomb: Consultant; Ocular Therapeutix: Consultant