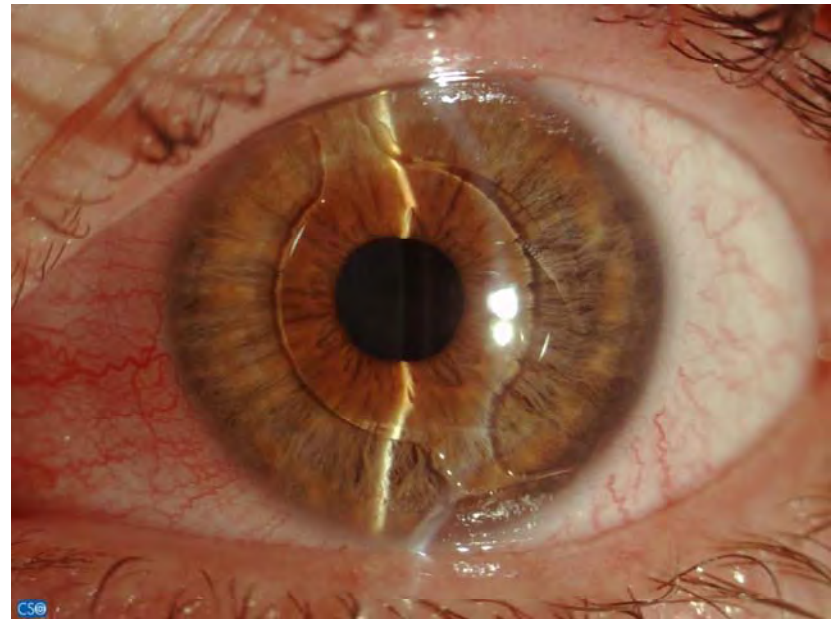






n



# Multifocal IOL-unhappy pt

- Trial with toric contact lens prior to laser enhancement
- Macula OCT-subclinical ERM may complicate pt satisfaction by reducing contrast sensitivity
- PCO-collection of lens epithelial cells on IOL steps?- when to perform YAG capsulotomy
- Centration of IOL on optical axis (specially in hyperopes)?
- Option to remove the IOL after first eye if anticipation of problem for the second?
- Perhaps bilateral implantation may be preferable?

# Customised bioptics with topography-guided laser refractive enhancements (tGLRE).

- **Purpose:** To evaluate the safety, efficacy and clinical parameters of tGLREs.
- **Setting:** The Laservision.gr Institute, Athens, Greece.
- **Methods:** 31 eyes of 18 consecutive patients that had underwent previously one of the following procedures: Multifocal, toric, accommodating or phakic IOL implantation, DSEK, lamellar or penetrating keratoplasty were treated with tGLRE PRK or LASIK and were evaluated pre- and 6 months post-operatively for: age, UCVA, BSCVA, refraction, topography, endothelium (ECC), and possible complications.
- **Results:** There were 21 LASIK and 10 PRK tGLRE. The mean age was 57 years (27 to 78) and mean values pre- and post-op were respectively: UCVA: 20/50, 20/25, BSCVA: 20/40, 20/25, Spherical equivalent reduction from 2.2 to 0.6 diopters, ECC: 1850, 1650, Follow-up: 5.5 months (3 to 38). No complications were encountered in his small group.
- **Conclusions:** tGLRE appear to be a safe and effective step in the bioptics visual rehabilitation of this variable group of cases.

# Evaluation of toric IOL implantation in cataract surgery.

**Purpose:** To evaluate the safety, efficacy and clinical parameters of the Acrysof Toric, IOL (Alcon, Fort Worth, TX) in cataract surgery.

**Methods:** 115 eyes of 78 consecutive patients were evaluated pre- and 6 months post-operatively for: age, UCVA, BSCVA, refraction, cylinder (C), topographic cylinder change (TCc), endothelium (ECC), degrees of planned-to-achieved IOL axis deviation angle of deviation planned to achieved IOL position (Ad), and possible complications. **Results:** The mean age was 67 years and mean values pre- and post-op were respectively: UCVA: 20/100, 20/28, BSCVA: 20/40, 20/24, Spherical equivalent reduction from 4.2 to 0.5D, C: -2.75D, -0.55 D, TCc: -0.45, ECC: 1850, 1650, Ad: 5 degrees. **Conclusions:** This toric IOL appears to be safe and effective in facilitating emmetropia in cataract surgery.

-

# Clinical evaluation of foldable acrylic phakic IOL (fP) implantation.

- **Purpose:** To evaluate the safety, efficacy and clinical parameters of the Cache, phakic IOL (Alcon, Fort Worth, TX) in the visual rehabilitation of high myopia (HM).
- **Methods:** 15 eyes of 8 consecutive patients were evaluated pre- and 6 months post-operatively for: age, UCVA, BSCVA, refraction, cylinder (C), topographic cylinder change (TCc), endothelium (ECC and possible complications.
- **Results:** The mean age was 27 years and mean values pre- and post-op were respectively: UCVA: 20/400, 20/25, BSCVA: 20/25, 20/18, Spherical equivalent reduction from 10.2 to 0.5 diopters, C: -1.75D, -1.25 D, TCc: -0.35, ECC: 2650, 2550. No complications were encountered in his small group.
- **Conclusions:** This fP appears to be safe and effective in HM.

# Speakers

1-Prof Kohnen Thomas-**Frankfurt, Germany:**

*ACRYSOF ReSTOR +3 IOL: Pre-Op & Intra-Op pearls and Clinical Outcomes*

2-Dr. Karamaounas Nikolaos-**Patra, Greece:**

*Advance of Cataract Surgery with INFINITI IP*

3-Dr. Smachliou Petros, **Athens, Greece:**

*Experience with ACRYSOF TORIC IOL*

4-Mavroudis Leonidas-**Thessaloniki, Greece:**

*CACHET IOL: Product Clinical Overview, indications, surgical pearls*