

## Innovations in Femtosecond Laser Technology – The Use of the Wavelight® FS200 Laser for Flap Cutting during LASIK Surgery

Anastasios John Kanellopoulos

Clinical Professor, Department of Ophthalmology, New York University Medical School, and Medical Director, Laservision Institute, Athens

### Abstract

Laser-assisted *in situ* keratomileusis (LASIK) involves the creation of a corneal flap and remodelling of the corneal stroma. This conventionally used a mechanical microkeratome but these devices are associated with variations in the flaps produced. The development of femtosecond excimer laser technology over the past 10 years has markedly improved the safety and efficiency of flap cutting during LASIK and provides superior performance. The Wavelight® FS200 laser is a recent development in femtosecond laser systems. This instrument is calibrated when switched on and prior to application of the applanation cone to the cornea surface, ensuring consistency in flap cutting. The Wavelight FS200 laser has a rapid firing speed that reduces the energy requirement, makes flap lifting easier, reduces procedure time and improves patient comfort. The system also provides consistency of flap diameter and thickness and allows for individualisation of flap morphology based on the patient's condition. This article discusses clinical experience with the Wavelight FS200 laser for flap cutting in LASIK surgery.

### Keywords

Laser-assisted *in-situ* keratomileusis (LASIK), femtosecond excimer laser, corneal flap cutting, corneal stroma, flap consistency

**Disclosure:** Anastasios John Kanellopoulos is a consultant for Alcon in the US, which produces the Wavelight® FS200 laser. He is also a consultant for Wavelight, Germany; Bausch and Lomb, US; Priavision, US; Seros Medical, US; KeraMed, US; Revision Optics, US; and Katena, US.

**Received:** 23 August 2010 **Accepted:** 15 September **Citation:** *European Ophthalmic Review*, 2010;4:40–3

**Correspondence:** Anastasios John Kanellopoulos, MD, Laservision.gr, 17 Tsocha Street, 11521 Ampelokipoi, Greece. E:ajk@brilliantvision.com

**Support:** The publication of this article was funded by Alcon Laboratories. The views and opinions expressed are those of the author and not necessarily those of Alcon Laboratories.

The laser-assisted *in situ* keratomileusis (LASIK) procedure is a safe, painless and quite common corneal refractive surgical procedure for the correction of myopia, hyperopia and astigmatism. It involves the initial creation of a corneal flap, followed by remodelling of the corneal stroma using an excimer laser. Finally, the corneal flap is placed back onto the corneal stroma and allowed to heal.

The success and safety of laser treatment during LASIK surgery is highly dependent on the precision and consistency of the corneal flap created. Mechanical microkeratomes have been conventionally used for flap-cutting during LASIK surgeries and their use has been associated with a good efficacy and safety record.<sup>1</sup> Despite this good performance record and innovations in mechanical microkeratomes, however, their use is still associated with variations in the morphology, diameter and thickness of the corneal flap created.<sup>2–5</sup> Furthermore, many complications of LASIK surgery are related to flap-cutting with mechanical microkeratomes. For example, rare complications such as free caps, epithelial abrasions, incomplete cuts and button holes have been reported.<sup>6–10</sup>

Femtosecond lasers were introduced nearly 10 years ago. Considerable progress has since been made in femtosecond technology, with improvements in flap thickness reproducibility,<sup>11,12</sup> stromal bed quality,<sup>13</sup> biochemical outcomes<sup>14,15</sup> and wavefront measurements.<sup>16</sup> The use of femtosecond laser technology

represents a new approach to improving the safety and efficiency of flap-cutting during LASIK and femtosecond laser-assisted LASIK. This is commonly referred to as All-Laser LASIK.

It is now well established that femtosecond lasers are superior to mechanical microkeratomes for flap cutting during LASIK surgery.<sup>17–24</sup> It has been shown in several studies that the thickness of the corneal flaps created with femtosecond lasers is less variable than flaps created with mechanical microkeratomes.<sup>17–19,25,26</sup> Currently available femtosecond lasers, the last of which is a recent introduction to the field, include:

- the Femto LDV™ Femtosecond Surgical Laser (Femtec Laser);
- the IntraLase FST™ Laser;
- the LensAR Laser System™;
- the VisuMAX Femtosecond Laser System; and
- the Wavelight® FS200 Femtosecond Laser.

The FS200 has been used in several laboratory corneal procedures in cadaver corneas in the Laservision Institute laboratory in Athens, Greece. Some of these investigative laboratory procedures included LASIK flap simulation, intracorneal pocket crosslinking (CXL), lamellar and penetrating keratoplasty simulation and intracorneal keratoprosthesis placement. Following the granting of a CE mark for the device, the FS200 has been also utilised in LASIK practice at the Institute. The aim of this article is to discuss the mechanics of, and

clinical experience with, the WaveLight FS200 laser for flap cutting during LASIK surgery.

### The Mechanics of the WaveLight® FS200 Laser for Flap Cutting

A mechanical microkeratome is a blade-like instrument that utilises shear force to mechanically separate the cornea and create the flap. By contrast, femtosecond lasers, such as the WaveLight FS200, do not actually cut the cornea, but instead create a flap by using a photodisruption method.<sup>27</sup>

The WaveLight FS200 is illustrated in *Figure 1*. Flap cutting with the WaveLight FS200 laser initially involves the placement of an automated suction ring onto the corneal surface in order to immobilise the eye. Subsequently, a computer-controlled applanation cone is docked into the suction ring. The femtosecond then releases infrared laser pulses in a raster pattern onto the cornea. This results in the formation of small cavitation bubbles within the cornea. The creation of thousands of such cavitation bubbles in a lamellar pattern leads to the creation of a cleavage plane within the cornea. Subsequently, laser pulses are fired in a peripheral circular pattern onto the corneal stroma in order to create a vertical side cut and a hinge. The suction of the WaveLight FS200 laser is turned off and the corneal flap lifted, thereby exposing the corneal stroma (the middle section of the cornea).

### Clinical Experience

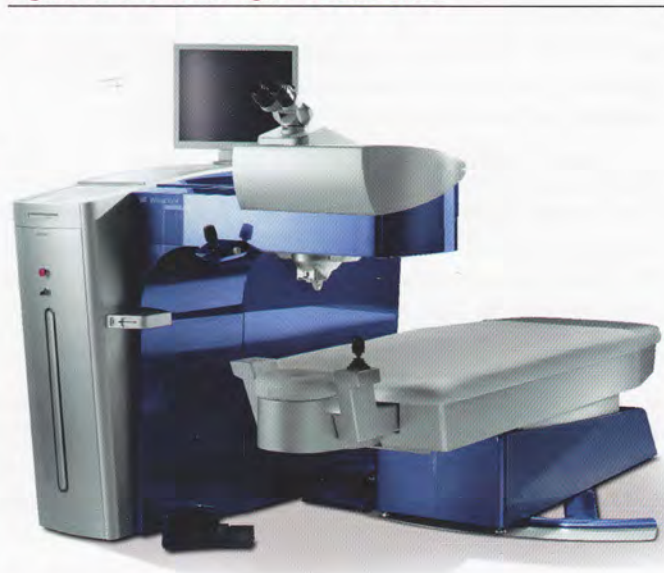
At the Laservision Institute, the WaveLight FS200 laser has been used for flap-cutting during LASIK surgery. In the experience gained at the Institute, it has been noted that this laser system has several features that allow the improvement of safety, precision and efficiency of the flap-cutting procedure.

An important feature of the WaveLight FS200 laser is the calibration of the system to ensure consistency. Two instances of calibration occur. The first is when the machine is initially turned on and the second is just prior to applying the cone to the cornea surface. During the second calibration, the distance between the focusing device and the anterior surface of the cone is measured to compensate for deviations in applanation glass thickness. If the laser cone is outside the pre-determined parameters, the WaveLight FS200 laser will reject the use of that particular cone and move onto a second one. This is an important safety feature, as it allows the WaveLight FS200 laser to choose the most appropriate laser cone to ensure consistent flap thickness.


The complications associated with flap cutting using mechanical microkeratomomes – such as button holes, free flaps and incomplete flaps – have not been observed when using the WaveLight FS200 at the Laservision Institute. The availability of a screen and a microscope with the WaveLight FS200 laser mean that the surgeon can clearly see the entire flap-cutting procedure. These features provide the opportunity for improved physician confidence and control throughout the procedure.

The WaveLight FS200 laser also offers potential benefits to the patient in terms of a shortened procedure time. The flap-cutting period is probably the most uncomfortable part of the LASIK procedure, but the WaveLight FS200 laser has a rapid firing speed of 200kHz, which takes approximately six to seven seconds for the laser to create a 9.0mm

**Figure 1: The WaveLight® FS200 Laser**



**Figure 2: Flap Cutting Edges Created Using the WaveLight® FS200 Laser**



Source: Alcon.

**Figure 3: Stromal Bed Quality Observed Using the WaveLight® FS200 Laser**



Source: Alcon.

corneal flap. Furthermore, the total procedure time for flap-cutting with the WaveLight FS200 laser has been estimated to be approximately 30 seconds from when the suction is turned on to when it is turned off. The fast firing speed of the laser also reduces the energy requirement and makes flap lifting easier.

The efficiency of the procedure is further enhanced through the use of an exhaust channel that minimises the build-up of an opaque bubble layer during the flap-cutting procedure. This makes the procedure more efficient and comfortable for the patient as the physician does not have to wait for the opaque bubble layer to dissipate in order to perform the ablation.

The thickness of LASIK flaps is crucial for accurately predicting the residual stroma bed after excimer ablation as well as for preventing complications after LASIK surgery, such as corneal ectasia (a long-term complication).<sup>28,29</sup> At the Laservision Institute, the WaveLight FS200 laser has provided improved precision and consistency of the flap diameter and thickness compared with mechanical microkeratomes. A magnified image of the flap-cutting edges created using the WaveLight FS200 laser is shown in *Figure 2* and an image of the stromal bed is shown in *Figure 3*.

The WaveLight FS200 laser allows individualisation of the flap shape, size and hinge position, allowing the surgeon to optimise the flap morphology and dimensions based on the patient's condition. For example, flaps with a thickness of approximately 110µm and a diameter of 8mm are generally created for cases of myopia, whereas for cases of hyperopia they are approximately 140µm thick and 9.5mm in diameter.

Using the WaveLight FS200 laser, the surgeon can also create very large flaps of up to 10mm in diameter. For these types of flaps, the exhaust plume is even more important as it has been shown that bubbles are more common when thicker and smaller diameter flaps are created.<sup>30</sup> Furthermore, creating flaps with a large diameter may also compensate for any decentration relative to performing the ablation.<sup>31</sup>

Finally, the WaveLight FS200 laser has network connectivity with the WaveLight diagnostics and WaveLight EX500 Excimer laser system. It is possible for the ablation profile from the excimer laser to be displayed on the screen of the femtosecond laser. This allows the surgeon to be aware of where the ablations are going to take place and he/she can then create the corneal flap accordingly.

## Limitations

The cost and availability of femtosecond lasers remain important concerns and the use of femtosecond lasers should be evaluated on

the basis of a cost versus benefit analysis. Nevertheless, the availability of femtosecond platforms is becoming less of a problem as a result of the increasing popularity of this technology. Although there have been no reports of any complications with the WaveLight FS200 laser, rare complications with other femtosecond lasers have been reported. These include epithelial ingrowth and new syndromes, such as transient light sensitivity.<sup>32</sup>

## Conclusions and Future Research

Femtosecond lasers are now considered to be superior to mechanical microkeratomes for flap-cutting during LASIK surgeries. It is therefore likely that, in time, femtosecond lasers will replace microkeratomes for corneal refractive procedures, particularly for flap-cutting during LASIK procedures.

Experience gained at the Laservision Institute using the recently-introduced WaveLight FS200 femtosecond laser revealed several advantageous features compared with mechanical microkeratomes that allow for a more efficient, precise and safer procedure. These features include:

- a rapid laser firing speed;
- high visibility for the majority of the flap-cutting procedure;
- laser cone calibration methods;
- good network connectivity; and
- the opportunity to individualise flap shape and size.

Finally, there have been initial reports of promising results with the WaveLight FS200 laser for other corneal procedures, such as the implantation of a presbyopic lens and the creation of tunnels for corneal rings. Further research into these applications would be of considerable interest. ■



Anastasios John Kanellopoulos is a Clinical Professor in the Department of Ophthalmology at the New York University Medical School and Medical Director of the Laservision Institute in Athens in Greece. He is an Eye Surgeon specialising in cornea transplantation, complicated glaucoma and refractive surgery. He has subspecialised in external diseases and cornea and refractive surgery, with Fellowship training at Cornell University Medical College and the Massachusetts Eye

and Ear Infirmary and Glaucoma at Harvard Medical School. He has been a regular clinical consultant in cornea, refractive, and cataract surgery for several international centres in Europe and the Middle East. He has published over 30 original papers in peer-reviewed journals, over 10 book chapters and many paper and poster presentations in the major eye meetings worldwide. Professor Kanellopoulos is a member of the Cornea Committee of the American Society of Cataract and Refractive Surgery (ASCRS) and the International Steering Committee of the American Academy of Ophthalmology/International Society of Refractive Surgeons (AAO/ISRS).

1. Kanellopoulos AJ, Pe LH, Kleiman H, Moria M2 single use microkeratome head in 100 consecutive LASIK procedures, *J Refract Surg*, 2005;21(5):476-9.
2. Arbelaez MC, Nidek MK 2000 microkeratomeclinical evaluation, *J Refract Surg*, 2002;18:S347-51.
3. Shemesh G, Dotan G, Lipshitz I, Predictability of corneal flap thickness in laser in situ keratomileusis using three different microkeratomes, *J Refract Surg*, 2002;18:S347-51.
4. Solomon KD, Donnenfeld E, Sandoval HP, et al., Flap Thickness Study Group, Flap thickness accuracy: comparison of 6 microkeratome models, *J Cataract Refract Surg*, 2004;30:964-77.
5. Uçakhan ÖÖ, Corneal flap thickness in laser in situ keratomileusis using the Summit Krumeich-Barraquer microkeratome, *J Cataract Refract Surg*, 2002;28:798-804.
6. Ambrósio R Jr, Wilson SE, Complications of laser in situ keratomileusis: etiology, prevention, and treatment, *J Refract Surg*, 2001;17:350-79.
7. Holzer MP, Vargas LG, Sandoval HP, et al., Corneal flap complications in refractive surgery: Part 1: development of an experimental animal model, *J Cataract Refract Surg*, 2003;29:795-802.
8. Juhasz T, Loesel FH, Kurtz RM, et al., Corneal refractive surgery with femtosecond lasers, *IEEE J Select Top Quantum Elec*, 1999;5:902-10.
9. Pallikaris IG, Papatzanaki ME, Siganos DS, et al., A corneal flap technique for laser in situ keratomileusis: human studies, *Arch Ophthalmol*, 1991;109:1699-702.
10. Stern D, Schoenlein RW, Pulliafito CA, et al., Corneal ablation by nanosecond, picosecond, and femtosecond lasers at 532 and 625 nm, *Arch Ophthalmol*, 1989;107:587-92.
11. Kim J-H, Lee D, Rhee K-I, Flap thickness reproducibility in laser in situ keratomileusis with a femtosecond laser: optical coherence tomography measurement, *J Cataract Refract Surg*, 2008;34:132-6.
12. Stahl JE, Durrie DS, Schwendeman FJ, et al., Anterior segment OCT analysis of thin IntraLase femtosecond flaps, *J Refract Surg*, 2007;23:555-58.

13. Sarayba MA, Ignacio TS, Binder PS, et al., Comparative study of stromal bed quality by using mechanical, IntraLase femtosecond laser 15- and 30-KHz microkeratomers, *Cornea*, 2007;26:446-51.
14. Dupps WJ Jr, Wilson SE, Biomechanics and wound healing in the cornea, *Exp Eye Res*, 2006;83:709-20.
15. Stonecipher K, Ignacio TS, Stonecipher M, Advances in refractive surgery: microkeratome and femtosecond laser flap creation in relation to safety, efficacy, predictability, and biomechanical stability, *Curr Opin Ophthalmol*, 2006;17:368-72.
16. Medeiros FW, Stapleton WM, Hammel J, et al., Wavefront analysis comparison of LASIK outcomes with the femtosecond laser and mechanical microkeratomers, *J Refract Surg*, 2007;23:880-87.
17. Binder PS, Flap dimensions created with the IntraLase FS laser, *J Cataract Refract Surg*, 2004;30:26-32.
18. Durrie DS, Kezirian GM, Femtosecond laser versus mechanical keratome flaps in wavefront-guided laser in situ keratomileusis: prospective contralateral eye study, *J Cataract Refract Surg*, 2005;31:120-26.
19. Kezirian GM, Stonecipher KG, Comparison of the IntraLase femtosecond laser and mechanical keratomers for laser in situ keratomileusis, *J Cataract Refract Surg*, 2004;30:804-11.
20. Kurtz RM, Horvath C, Liu HH, et al., Lamellar refractive surgery with scanned intrastromal picosecond and femtosecond laser pulses in animal eyes, *J Refract Surg*, 1998;14:541-48.
21. Nordan LT, Slade SG, Baker RN, et al., Femtosecond laser flap creation for laser in situ keratomileusis: six-month follow-up of initial U.S. clinical series, *J Refract Surg*, 2003;19:8-14.
22. Ratkay-Traub I, Juhasz T, Horvath C, et al., Ultra-short pulse (femtosecond) laser surgery: initial use in LASIK flap creation, *Ophthalmol Clin North Am*, 2001;14:347-55.
23. Ratkay-Traub I, Ferincz IE, et al., First clinical results with the femtosecond neodymium-glass laser in refractive surgery, *J Refract Surg*, 2003;19:94-103.
24. Tran DB, Sarayba MA, Bor Z, et al., Randomized prospective clinical study comparing induced aberrations with IntraLase and Hansatome flap creation in fellow eyes: potential impact on wavefront-guided laser in situ keratomileusis, *J Cataract Refract Surg*, 2005;31:97-105.
25. Binder PS, One thousand consecutive IntraLase laser in situ keratomileusis flaps, *J Cataract Refract Surg*, 2006;32:962-69.
26. Patel SV, Maguire LJ, McLaren JW, et al., Femtosecond laser versus mechanical microkeratome for LASIK; a randomized controlled study, *Ophthalmology*, 2007;114:1482-90.
27. Lubatschowski H, Overview of commercially available femtosecond lasers in refractive surgery, *J Refract Surg*, 2008;24:S102-07.
28. Amoils SP, Deist MB, Gous P, et al., Iatrogenic keratectasia after laser in situ keratomileusis for less than -4.0 to -7.0 diopters of myopia, *J Cataract Refract Surg*, 2000;26:967-77.
29. Seiler T, Koufala K, Richter G, Iatrogenic keratectasia after laser in situ keratomileusis, *J Refract Surg*, 1998;14:312-17.
30. Kaiserman I, Maresky HS, Bahar I, et al., Incidence, possible risk factors, and potential effects of an opaque bubble layer created by a femtosecond laser, *J Cataract Refract Surg*, 2008;34:417-23.
31. Slade SG, The use of the femtosecond laser in the customization of corneal flaps in laser in situ keratomileusis, *Curr Opin Ophthalmol*, 2007;18:314-17.
32. Touboul D, Salin F, Mortemousse B, et al., Advantages and disadvantages of the femtosecond laser microkeratome, *J Fr Ophthalmol*, 2005;28:535-46.