Combining Topography-Guided PRK With CXL: The Athens Protocol

Same-day simultaneous treatment stabilizes ectasia and enhances visual rehabilitation.

BY A. JOHN KANELLOPOULOS, MD

Following the initial research on corneal collagen crosslinking (CXL) by Seiler, Wollensak, and Spoerl,[1-4] we adopted this modality in 2002 at our center in Athens, Greece, to treat keratoconus and post-LASIK ectasia. Over the past 8 years, we have treated several hundred cases of keratoconus and post-LASIK ectasia with CXL, reducing the number of penetrating keratoplasties performed at our center by approximately 80%.

Long-term follow-up of our patient population has shown that CXL, when not performed in combination with another procedure, successfully halted the progression of ectasia. However, it did not help with the sometimes puzzling visual rehabilitation, especially in cases of high anisometropia and contact lens intolerance. In our experience, it is common for patients who have been stabilized by CXL to require a second procedure for visual rehabilitation.

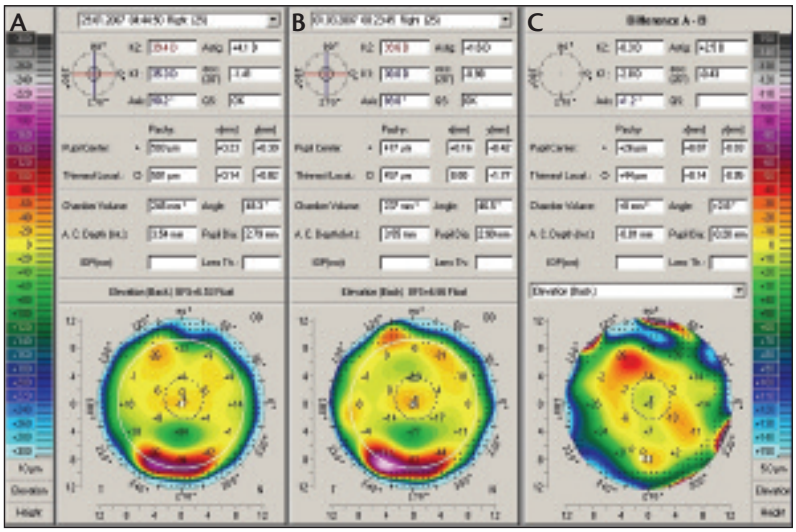

Figure 1. Figure 1. (A) Before the combined treatment, the cornea demonstrates marked central-inferior steepening consistent with ectasia. (B) At 2 years post-operative, topography revealed a flatter, more normalized cornea. (C) Comparison between pre- and postoperative topographies.

In response to these outcomes, we have converted to same-day simultaneous topography-guided partial PRK and CXL as a therapeutic intervention in patients with highly irregular corneas with keratoconus and progressive post-LASIK ectasia. In our technique, called the *Athens Protocol,* when CXL is performed immediately after topography-guided PRK, the potential for superficial stromal scarring is lessened and patients experience minimal haze.

A THERAPEUTIC APPROACH

When combined with CXL, topography-guided partial PRK is more of a therapeutic treatment than a refractive one. The Allegretto excimer laser platform (WaveLight Laser Technologie, AG, Erlangen, Germany), flattens some of the cone apex and an arcuate, broader area of the cornea away from the cone, usually in the superonasal periphery. This ablation pattern resembles part of a hyperopic treatment, causes some steepening or elevation adjacent to the cone, and effectively normalizes the

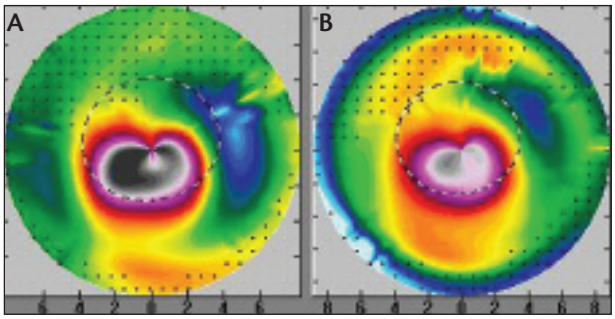

Figure 2. (A) Inferior steepening before topography-guided PRK and CXL. (B) At 16 months postoperative, the cornea demonstrated marked flattening of ectasia and cornea normalization.

cornea.[5] We theorize that the new, flatter, and less irregular corneal shape may perform better biomechanically in eyes with post-LASIK ectasia. The biomechanical strain caused by intraocular pressure and other factors, such as eye rubbing, may be redistributed as the corneal apex becomes a flatter and broader cone. This effect may be further strengthened with CXL.

SURGICAL TECHNIQUE

Customized excimer laser treatment with the Allegretto platform is guided by topography images, which is different from wavefront-guided excimer treatments. The topography-guided technique has not yet received approval from the US Food and Drug Administration (FDA).

We use the partial topography-guided PRK to normalize the cornea, reducing irregular astigmatism while treating part of the refractive error. We decrease the effective optical zone diameter to 5.5 mm (compared with our usual treatment diameter in routine PRK and LASIK cases of at least 6.5 mm) to ensure that we remove a minimal amount of tissue. We also plan approximately 70% treatment of cylinder and up to 70% sphere in order not to exceed 50 µm of stromal removal.

Following the placement of an aspirating lid speculum, a 50-µm phototherapeutic keratectomy at a 6.5-mm optical zone is performed to remove the corneal epithelium. Then the partial topography-guided PRK laser treatment is applied. A cellulose sponge soaked in mitomycin-C 0.02% is applied over the ablated tissue for 20 seconds, followed by irrigation with 10 mL of chilled balanced salt solution.

For the next 10 minutes, 0.1% riboflavin sodium phosphate ophthalmic solution (Priavision, Inc., Mento Park, California) is applied topically every 2 minutes. The corneal stroma rapidly soaks up the solution, because the central Bowman's membrane has been removed. Following the initial administration of riboflavin, a Keracure protoype device

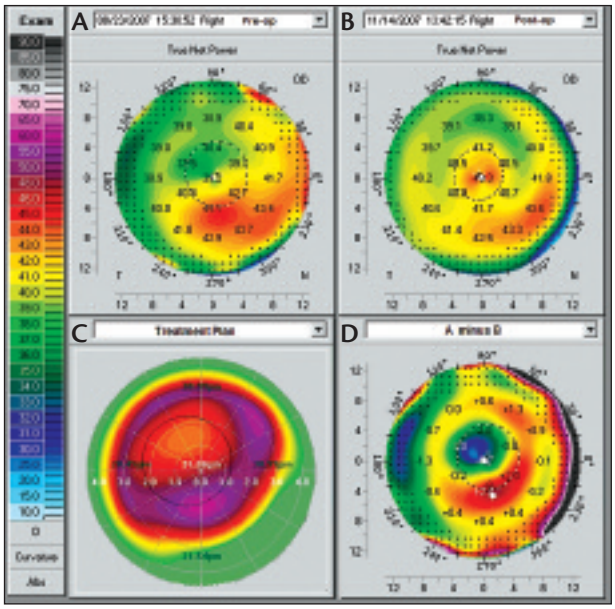

Figure 3. (A) Three years after LASIK, this eye had irregular astigmatism and marked inferior corneal steepening. (B) Three months after topography-guided PRK and CXL, the cornea is flatter and more normalized (UCVA, 20/15). (C) A topographic reproduction of the topography-guided PRK treatment plan with the Wavelight excimer laser. This platform plans to remove tissue in an irregular fashion to normalize the corneal ectasia seen in 3A. (D) The comparison map deriving from subtracting image B from A represents the topographic difference in this eye 3 months after the combined treatment. The paracentral flattening is self-explanatory, as the PRK and CXL have flattened the cone apex. The superonasal arcuate flattening represents the part-hyperopic correction that topography-guided treatment achieved in order to accomplish steepening in the area central to this arc. Thus, the topography-guided treatment has normalized the ectatic cornea by flattening the cone apex and steepening the rest of the central cornea.

(Priavision, Inc.), with four diodes emitting 365 to 375 nm of UV-A light, is used to project 3 mW/cm^2 of radiance at a distance of 2.5 cm onto the surface of the cornea for 30 minutes. A bandage contact lens is placed on the cornea at the completion of the combined procedure.

TAKE-HOME MESSAGE

- When CXL is performed immediately after topography-guided PRK, the potential for superficial stromal scarring is lessened, and patients experience minimal haze.
- Studies suggest that the Athens Protocol halted the progression of ectasia, improved UCVA and BCVA after LASIK, and delivered a synergistic effect to corneal flattening in eyes with keratoconus.

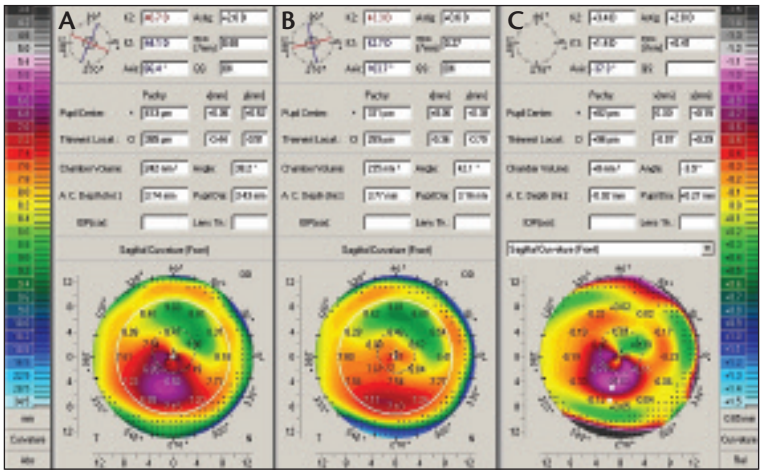

Figure 4. Pentacam comparison in right eye. (A) The column on the left shows data and topography before the combined treatment. (B) Postoperative data and topography. (C) The difference between pre- and postoperative.

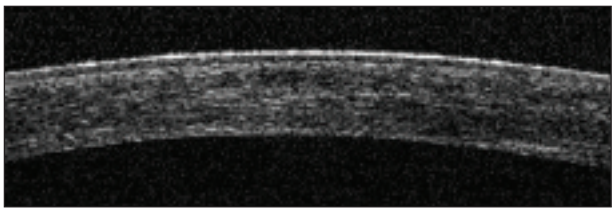

Figure 5. Optical coherence tomography of the central cornea 11 months after the combined procedure. The hyperreflectivity of the anterior two-thirds of the cornea demonstrates the CXL effect. The hypereflective demarcation in the middle of the cornea suggests a LASIK flap of more than 200 µm.

After CXL, the patient is instructed to use topical ofloxacin four times per day for the first 10 days and prednisolone acetate 1% (Pred Forte; Allergan, Irvine, California) four times per day for 60 days. Protection from all natural light with sunglasses is encouraged along with 1,000 mg of oral vitamin C daily for 60 days. The bandage contact lens is removed after complete reepithelialization, which usually occurs around day 5.

KERATOCONUS

In a large consecutive series, I compared the visual rehabilitation of progressing keratoconus in same-day simultaneous topography-guided PRK and CXL versus sequential CXL and PRK.[6]

The study included 325 eyes divided into two groups. The first group (sequential group; n=127 eyes) underwent CXL with subsequent topography-guided PRK performed 6 months later, and the second group (simultaneous group; n=198 eyes) underwent CXL and PRK in a combined procedure on the same day. Mean follow-up was 36 ±18 months (range, 24 to 68 months).

At the final follow-up for the sequential group, the mean UCVA improved from 0.9 ±0.3 (logMAR) to 0.49 ±0.25 (logMAR), and mean BCVA improved from 0.41 ±0.25 (logMAR) to 0.16 ±0.22 (logMAR). Mean reduction in spherical equivalent refraction was 2.50 ±1.20 D, mean haze score was ±0.5, and mean reduction in keratometry was 2.75 ±1.30 D.

In the simultaneous group, mean UCVA improved from 0.96 ±0.2 (logMAR) to 0.3 ±0.2 (logMAR), and mean BCVA improved from 0.39 ±0.3 (logMAR) to 0.11 ±0.16 (logMAR). Mean reduction in spherical equivalent refraction was 3.20 ±1.40 D, mean haze score was 0.5 ±0.3, and mean reduction in keratometry was 3.50 ±1.30 D.

In both groups, endothelial cell count was unchanged from preoperative to the last follow-up (P <.05). The simultaneous group had statistically significantly greater improvements in UCVA and BCVA, a greater mean reduction in spherical equivalent refraction and keratometry, and less corneal haze (P <.05).

Based on these results, the Athens Protocol appears to be superior to sequential CXL and PRK. Same-day simultaneous topography-guided PRK and CXL appears to deliver a synergistic effect to corneal flattening, along with the advantages of less surgery and no removal of crosslinked tissue. These findings suggest that, with early diagnosis of keratoconus, use of CXL with a properly refined technique and appropriate follow-up may reduce the need for corneal transplantation.

POST-LASIK ECTASIA

Results of a case series, which I presented at the American Society of Cataract and Refractive Surgery (ASCRS) in Boston,[7] showed that the same-day topography-guided PRK and CXL approach appeared to halt ectasia progression and improve UCVA and BCVA by reducing myopic and irregular astigmatic refractive errors in eyes that would otherwise have been severely handicapped due to the development of iatrogenic ectasia after LASIK.

In this study, all PRK procedures were intended to reduce corneal thickness by a maximum of 50 µm, regardless of the degree of existing refractive error, to avoid exacerbation of the ectasia. The partial topopgraphy-guided PRK and CXL procedure was performed an average of 18.4 months after primary LASIK surgery (range, 4–51 months; mean follow-up, 34 months). Thirty-two consecutive eyes with ectasia

underwent PRK with the Allegretto system immediately followed by CXL (7 mW/cm^2) for 15 minutes with 0.1% topical riboflavin sodium phosphate. Of the 32 eyes, 28 had an improvement in UCVA. In 11 eyes, post-CXL UCVA was greater than 20/30, and in two eyes it was worse than 20/60. BCVA was 20/40 or better in 28 eyes and 20/25 or better in 14 eyes. Four eyes showed some topographic improvement but no improvement in BCVA.

The mean refractive error decreased by more than 2.50 D in 27 of eyes and increased in three eyes. Mean spherical equivalent refraction was -1.75 D. One of the eyes required a subsequent penetrating keratoplasty. Grade 2 or higher corneal scarring was present in two eyes.

CONCLUSION

We have seen clinical stabilization of ectasia in post-LASIK and keratoconus cases with the use of CXL (Figures 1-5). The effect appears to be improving even at 6 years postoperative. This lasting beneficial change can be attributed to the slow reexpansion of the corneal stroma following the initial CXL procedure. Larger prospective, randomized, comparative studies establishing the safety and efficacy of this treatment are necessary to further validate these results.

Our early clinical findings suggest that CXL may have a wider application to reduce corneal swelling and as a potential adjunct in routine LASIK cases. This could potentially enhance flap adherence to the underlying stroma and reduce the negative biomechanical effect of flap-making in LASIK. ■

A. John Kanellopoulos, MD, is the Director of Laservision Eye Institute, Athens, Greece. He is a Clinical Associate Professor of Ophthalmology at New York University Medical School. Dr. Kanellopoulos states that he has no financial interest in the products or companies mentioned. He is a member of the CRST Europe *Editorial Board. Dr. Kanellopoulos may be reached at tel: +30 21 07 27 27 77; e-mail: ajk@laservision.gr.*

1. Wollensak G, Spoerl E, Seiler T. Stress-strain measurement of human and porcine corneas after riboflavin-ultraviolet-A-induced cross-linking. *J Cataract Refract Surg.* 2003;29(9):1780-1785.
2. Wollensak G, Spoerl E, Seiler T. Riboflavin/ultraviolet-a-induced collagen crosslinking for the treatment of keratoconus. *Am J Ophthalmol.* 2003;135(5):620-627.
3. Wollensak, G. Crosslinking treatment of progressive keratoconus: new hope. *Curr Opin Ophthalmol.* 2006;17(4):356-360.
4. Mazzotta C, Balestrazzi A, Traversi C, et al. Treatment of progressive keratoconus by riboflavin-UVA-induced cross-linking of corneal collagen. *Cornea.* 2007;26(4):390-397.
5. Kanellopoulos AJ. Managing highly distorted corneas with topography-guided treatment. Paper presented at: the Refractive Surgery SubspecialtyDay, American Academy of Ophthalmology Annual Meeting; November 10-13, 2007; New Orleans, Louisiana.
6. Kanellopoulos AJ. Comparison of sequential vs same-day simultaneous collagen cross-linking and topography-guided PRK for treatment of keratoconus. *J Refract Surg.* 2009;25(9):S812-S818.
7. Kanellopoulos AJ. Long-term follow-up of simulataneous CXL and topography-guided PRk for post-LASIK ectasia, Paper presented at: the American Society of Cataract and Refractive Surgery. April 10, 2010; Boston.