

Comparison of Sequential vs Same-day Simultaneous Collagen Cross-linking and Topography-guided PRK for Treatment of Keratoconus

Anastasios John Kanellopoulos, MD

ABSTRACT

PURPOSE: The safety and efficacy of corneal collagen cross-linking (CXL) and topography-guided photorefractive keratectomy (PRK) using a different sequence and timing were evaluated in consecutive keratoconus cases.

METHODS: This study included a total of 325 eyes with keratoconus. Eyes were divided into two groups. The first group (n=127 eyes) underwent CXL with subsequent topography-guided PRK performed 6 months later (sequential group) and the second group (n=198 eyes) underwent CXL and PRK in a combined procedure on the same day (simultaneous group). Statistical differences were examined for pre- to postoperative changes in uncorrected (UCVA, logMAR) and best-spectacle-corrected visual acuity (BSCVA, logMAR), manifest refraction spherical equivalent (MRSE)/refraction, keratometry (K), topography, central corneal thickness, endothelial cell count, corneal haze, and ectatic progression. Mean follow-up was 36±18 months (range: 24 to 68 months).

RESULTS: At last follow-up in the sequential group, the mean UCVA improved from 0.9±0.3 logMAR to 0.49±0.25 logMAR, and mean BSCVA from 0.41±0.25 logMAR to 0.16±0.22 logMAR. Mean reduction in spherical equivalent refraction was 2.50±1.20 diopters (D), mean haze score was 1.2±0.5, and mean reduction in K was 2.75 ±1.30 D. In the simultaneous group, mean UCVA improved from 0.96±0.2 logMAR to 0.3±0.2 logMAR, and mean BSCVA from 0.39±0.3 logMAR to 0.11±0.16 logMAR. Mean reduction in spherical equivalent refraction was 3.20±1.40 D, mean haze score was 0.5±0.3, and mean reduction in K was 3.50±1.3 D. Endothelial cell count was unchanged ($P<.05$) in both groups. Statistically, the simultaneous group did better ($P<.05$) in all fields evaluated, with improvement in UCVA and BSCVA, a greater mean reduction in spherical equivalent refraction and keratometry, and less corneal haze.

CONCLUSIONS: Same-day simultaneous topography-guided PRK and CXL appears to be superior to sequential CXL with later PRK in the visual rehabilitation of progressing keratoconus. [*J Refract Surg.* 2009;xx:xxx-xxx.] doi:10.3928/1081597X-2009

Keratoconus is a bilateral, non-symmetric, noninflammatory progressive corneal degeneration that frequently manifests in post-pubescent young adults as progressive steepening attributed to biomechanical stromal collagen weakening. Its incidence has been reported to be 1 in 2000 in the general population,^{1,2} but approximately four-fold greater among certain ethnic groups. The increased number among eyes undergoing screening for laser refractive surgery suggests the prevalence may be higher. Current surgical/nonsurgical interventions such as spectacles and contact lenses, intracorneal ring segment implantation,^{3,4} lamellar keratoplasty,⁵ and, the gold standard, penetrating keratoplasty,⁶ although popular, have limitations.^{7,8}

In recent years, basic laboratory studies and subsequent clinical studies have demonstrated stiffening of the cornea with use of ultraviolet A (UVA) light and riboflavin solution as a photosensitizer-initiated corneal collagen cross-linking (CXL) with no loss in corneal transparency. The CXL procedure has demonstrated the revolutionary potential for retarding or eliminating the progression of keratoconus and postoperative LASIK ectasia.⁹⁻¹⁷

We have performed over 1000 CXL treatments in our facility over the past 7 years both for postoperative LASIK ectasia and keratoconus with satisfactory outcomes. We have also demonstrated that topography-guided ablation of the cross-linked corneal stroma can “normalize” the highly irregular corneal surface in these eyes by reducing irregular astigmatism and often reducing the refractive error as well, providing patients with improved visual outcomes.¹⁸⁻²¹

From the Laservision.gr Institute, Athens, Greece; New York University Medical College and Manhattan Eye, Ear and Throat Hospital, New York, NY.

Presented in part as a poster at the annual ARVO meetings in 2004-2008; an invited lecture at the Annual ISRS/AAO Refractive Surgery Subspecialty Day, November 9-10, 2007, Las Vegas, Nev; a paper at the annual ESCRS symposium, September 11, 2008, Berlin, Germany; and a paper at the 4th International Congress of Corneal Cross-linking, December 5-6, 2008, Dresden, Germany.

Correspondence: Anastasios John Kanellopoulos, MD, Laservision.gr Institute, 17 Tsocha St, Athens 11521, Greece. Tel: 30 210 7472777; Fax: 30 210 7472789; E-mail: ajk@brilliantvision.com

The clinical results of a novel, same-day, simultaneous approach of topography-guided photorefractive keratectomy (PRK) and CXL for keratoconus²² are presented and retrospectively compared to the data from our previous experience of performing CXL first and PRK at least 6 months later. The outcomes of these two groups are compared in a retrospective case series with follow-up of 1 to 5 years.

PATIENTS AND METHODS

PATIENT SELECTION

All patients were enrolled in our Athens clinical facility. Once a diagnosis of keratoconus was confirmed (see below), patients were informed of various popular options, including CXL. Being neither FDA approved nor CE Marked (in cases treated prior to December 2006), informed consent was obtained from all patients and the surgery was performed in the following sequence: CXL first with topography-guided PRK at least 6 months later in eyes treated from August 2003 to May 2005 (sequential group). After gaining significant experience, we shifted our approach to same-day simultaneous customized topography-guided PRK and CXL in eyes treated from June 2005 to May 2008 (simultaneous group).

DIAGNOSIS OF KERATOCONUS

A diagnosis of progressive keratoconus was made in all patients (all aged <30 years), who developed progressive corneal steepening of at least 1.00 diopter (D) in keratometry, associated with a documented progression of increasing myopia and/or astigmatism over a period of 3 or more months. These findings were in parallel with increasing inferior corneal steepening and thinning to no less than 350 μm , based on videokeratography and pachymetry. Preoperative clinical data and topography were used as a baseline. Progression of the myopic refractive error with or without progression of the manifest astigmatism, decreasing uncorrected visual acuity (UCVA), loss of best spectacle-corrected visual acuity (BSCVA), progressive inferior corneal steepening on topography, and/or decreasing inferior corneal thickness were findings in all cases.

CLINICAL EXAMINATION

Each patient underwent manifest refraction before and 30 minutes after administration of one drop of 1% tropicamide solution (Akorn Inc, Lake Forest, Ill), as well as measurement of UCVA and BSCVA that was recorded in a 20-foot lane using high contrast Snellen visual acuity testing and then converted to logMAR scale values. A slit-lamp microscopic examination performed by the author confirmed invariably in all cases

the presence of keratoconus either by the presence of a Fleischer ring, central or paracentral corneal thinning with prominent cornea nerves, and/or Vogt's striae. Keratometry readings were obtained by videokeratography (Topolyzer; WaveLight Laser Technologie AG, Erlangen, Germany) and by two tomography-based topography devices—Orbscan II (Bausch & Lomb, Rochester, NY) and Pentacam (Oculus Optikgeräte, Wetzlar, Germany). Pachymetry was performed using all of the following instruments: Pentacam, Orbscan II, and ultrasonic EchoScan U.S.-1800 (NIDEK Co Ltd, Gama-gori, Japan). The minimal measurement in each case was used as the cornea thickness value, due to the importance of referencing the thinnest point. Specular microscopy was performed using the Konan specular microscope (Konan Medical, Boston, Mass).

Our technique of sequential CXL followed by topography-guided PRK at a later date has been reported previously.^{20,21} Both procedures have received CE Marking for clinical use (CXL in 2006, topography-guided PRK in 2003) within the countries of the European Union, including Greece. Topography-guided ablations with the WaveLight platform and CXL have not received FDA approval to date. As this is a novel approach and may be unfamiliar to most readers, the same-day simultaneous approach of topography-guided PRK and then CXL is described.

STEP 1: PARTIAL, SPHERICALLY CORRECTED TOPOGRAPHY-GUIDED PRK

We have devised this technique based on the proprietary WaveLight customized platform (Topolyzer). Use of the topography-guided platform with this device to normalize irregular corneas, including those with ectasia, has been reported previously.²³⁻²⁵

This proprietary software utilizes topographic data from the linked topography device (Topolyzer). By default, it permits the consideration of eight topographies (of predetermined threshold accuracy), averages the data, and enables the surgeon to adjust the desired postoperative cornea asphericity (chosen as zero in all cases), the inclusion, or not, of tilt correction (no tilt was chosen in all cases), as well the adjustment of sphere, cylinder, axis, and treatment zone (an optical zone of 5.5 mm was chosen in all cases). The image of the planned surgery is generated by the laser software.^{20,21}

We used topography-guided PRK to normalize the cornea, by reducing irregular astigmatism and also treating part of the refractive error. To ensure minimal tissue removal, the effective optical zone diameter was decreased to 5.5 mm (compared to our usual treatment diameter in routine PRK and LASIK cases of at least 6.5 mm). We also planned ~70% treatment of cylinder

and whatever level of sphere (up to 70%), so as not to exceed 50 μm in planned stromal removal. The value of 50 μm was chosen arbitrarily by the author, based on experience with this platform in irregular corneas.

Following the placement of an aspirating lid speculum (Rumex, St Petersburg, Fla), 20% alcohol solution was placed within a 9-mm titanium LASEK trephine (Rumex) for 20 seconds after which the epithelium was wiped off with a dry Weck-cell sponge. The laser treatment was then applied. A cellulose sponge soaked in mitomycin C 0.02% solution was applied over the ablated tissue for 20 seconds followed by irrigation with 10 mL of chilled balanced salt solution.

STEP 2: COLLAGEN CROSS-LINKING

For the next 10 minutes, 0.1% riboflavin sodium phosphate ophthalmic solution (Priavision, Merlo Park, Calif) was applied topically every 2 minutes. The solution appeared to “soak” in the cornea stroma rapidly, as it was centrally devoid of Bowman’s membrane. Following the initial riboflavin administration, four diodes, emitting UVA light of approximately 370 nm wavelength (365 to 375 nm) and 3 mW/cm² radiance at 2.5 cm was projected onto the surface of the cornea for 30 minutes. A “Keracure” prototype device was used (Priavision). The Keracure device has a built-in beeper that alerts the clinician every 2 minutes during the 30-minute treatment to install the riboflavin solution in a timely fashion. A bandage contact lens was placed on the cornea at the completion of the procedure.

After CXL, topical ofloxacin (Allergan Inc, Irvine, Calif) was used four times a day for the first 10 days and prednisolone acetate 1% (Pred Forte, Allergan) was used four times a day for 60 days. Protection from all natural light with sunglasses was encouraged along with oral 1000 mg of Vitamin C daily for 60 days postoperatively (our standard postoperative management following PRK). The bandage contact lens was removed at approximately day 5 following complete reepithelialization.

All cases were evaluated before and after both treatments for age, sex, UCVA, BSCVA, refraction, keratometry (K), topography, central corneal thickness (CCT), endothelial cell count, corneal haze on a scale 0 to 4 (0=clear cornea, 1=mild haze, 2=moderate haze, 3=severe haze, and 4=reticular haze [obstructing iris anatomy]), and ectasia stability. These parameters were retrospectively collected and then statistically analyzed using paired *t* test.

RESULTS

Approximately 40% of patients complained of significant pain during the first postoperative night after

both CXL alone or when combined with simultaneous topography-guided PRK the same day, whereas others reported minimal discomfort. Reepithelialization occurred by postoperative day 4 in 90% of patients.

Specifically, 127 consecutive eyes (sequential group) had topography-guided PRK at least 6 months following CXL, whereas 198 eyes (simultaneous group) underwent topography-guided PRK followed immediately by CXL as a single procedure. Mean follow-up was 36 months (range: 14 to 68 months) from the time of the last procedure performed.

Mean endothelial cell count and morphology were unchanged in both groups (2650 \pm 150 cells/mm² preoperatively and 2700 \pm 140 cells/mm² postoperatively).

Mean patient age in the sequential group was 21.5 years (range: 17 and 29 years) and comprised 44 males and 32 females. At last follow-up, preoperative UCVA of 0.9 \pm 0.3 logMAR improved to 0.49 \pm 0.25 logMAR postoperatively, and BSCVA improved from 0.41 \pm 0.25 logMAR preoperatively to 0.16 \pm 0.22 logMAR postoperatively. The mean reduction in spherical equivalent refraction was 2.50 \pm 1.2 D, and the mean reduction in keratometry was 2.75 \pm 1.3 D. Mean haze score was 1.2 \pm 0.5. Mean central corneal thickness decreased from 465 \pm 45 μm preoperatively to 395 \pm 25 μm postoperatively.

Mean patient age in the simultaneous group was 20.5 years (range: 16 to 29 years) and comprised 53 males and 42 females. Mean UCVA improved from 0.96 \pm 0.2 logMAR preoperatively to 0.3 \pm 0.2 logMAR postoperatively, and BSCVA from 0.39 \pm 0.3 logMAR to 0.11 \pm 0.16 logMAR. Mean reduction in spherical equivalent refraction was 3.20 \pm 1.4 D, and mean reduction in keratometry was 3.50 \pm 1.3 D. Mean haze score was 0.5 \pm 0.3, and central corneal thickness decreased from 475 \pm 55 μm preoperatively to 405 \pm 35 μm postoperatively.

Statistical comparison using paired *t* test revealed that the simultaneous group performed superiorly with a better BSCVA ($P<.001$), spherical equivalent reduction ($P<.005$), mean keratometry reduction ($P<.005$), and corneal haze score ($P<.002$) at final follow-up. No eye lost lines of UCVA or BSCVA.

Figure 1 shows representative corneal topographies from sequential Pentacam examinations in a 19-year-old patient from the simultaneous group (same-day simultaneous topography-guided PRK and CXL). The keratometric data changes \sim 3.50 D from 45.10 and 42.2 @ 130.5° preoperatively to 41.1 and 39.1 @ 114.1° postoperatively, whereas the visual and refraction data change from UCVA of 20/40 to 20/25 and -1.75 -3.00 @ 130 (20/30) to $+0.50$ -1.00 @ 115 (20/20) at 2-year follow-up.

Sequential vs Simultaneous Topography-guided PRK and CXL/Kanellopoulos

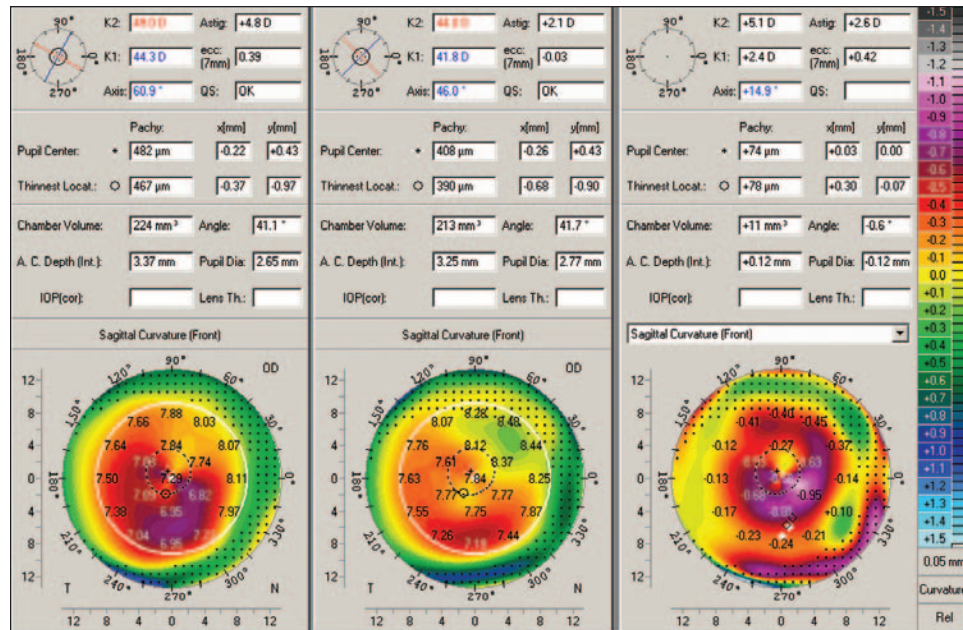


Figure 1. Representative corneal topographies from sequential Pentacam examinations are shown in a 29-year-old patient from the simultaneous group (same-day, simultaneous topography-guided photorefractive keratectomy [PRK] and corneal collagen cross-linking [CXL]). The difference map (right topography) is shown for the changes from preoperative (left topography) to 2 years postoperative (middle topography). The Pentacam data demonstrate the change of keratometric data from 49 and 44.3 @ 60.9° to 44 and 41.8 @ 46°. Changes in visual acuity and refraction data from pre- to postoperative were: uncorrected visual acuity 20/100 to 20/25 and best spectacle-corrected visual acuity (BSCVA) 20/30 with -2.75 -3.50 @ 65 to BSCVA 20/20 with $+0.50$ -1.00 @ 35 at 2 years. The difference map illustrates the surface change achieved by the simultaneous topography-guided PRK and CXL technique, which resembles a combined myopic PRK over the cone apex and an asymmetric hyperopic PRK in the periphery.

DISCUSSION

The technique of collagen CXL via a photosensitizing agent is similar to photopolymerization in polymers and has found a broad international application for keratoconus in recent years. Although multiple approaches have been used to treat ectatic corneal disorders, in cases of progressive disease, the gold standard treatment in many countries is penetrating keratoplasty with its established costs, morbidity, and attendant risks.

The mechanism of topography-guided ablation is the fitting of an ideal cornea shape (usually a sphere) under the present topography map with the ablation of tissue in between.

We have been able to use topography-guided treatments in highly irregular corneas that are beyond the limits of wavefront measuring devices,²³⁻²⁵ making this approach more efficient in treating highly irregular astigmatism, such as in keratoconus. It may also be applied in cases with some media opacity, such as in keratoconus eyes with corneal scars, as its measurements are based solely on the cornea surface reflection.

Topography-guided PRK flattens not only some of the cone “peak” but also an arcuate, broader area of the cornea away from the cone, usually in the superior nasal periphery; this ablation pattern will resemble part of a hyperopic treatment and thus will cause some amount of steepening, or elevation adjacent to the cone, effectively normalizing the cornea.²⁶ It is this core concept in the topography-guided PRK treatment that makes it, in our opinion, more therapeutic than refractive. We theorize additionally that the new, “flatter” and less irregular cornea shape may perform better biomechanically in keratoconus. Specifically, as the

cornea cone gives way to a flatter and “broader” cone, this may redistribute the biomechanical strain from the eye’s intraocular pressure and other factors (such as eye rubbing). This effect may be further enhanced with the CXL adjunct.

We have converted to same-day simultaneous topography-guided PRK and CXL in our clinical practice, represented herein by the cases in the simultaneous group, for three reasons: 1) the combination reduces the patient’s time away from work, 2) performing both procedures at the same time with topography-guided PRK first appeared to minimize the potential superficial stromal scarring resulting from PRK, and 3) when topography-guided PRK is performed after the CXL procedure, some of the cross-linked anterior cornea is removed, minimizing the potential benefit of CXL.

With the second reason, our initial experience in the cases in the sequential group suggested that if the practitioner waited between procedures, the damaged keratocytes would replenish and may become activated as fibroblasts after PRK, causing scarring even with the use of mitomycin C.²⁷ In these cases, we performed topography-guided PRK at least 6 months after CXL and encountered significant haze in 17 eyes, despite using MMC. When we employed CXL immediately after topography-guided PRK, we encountered minimal haze formation (2 cases with significant haze). The CXL procedure has been shown to “kill” keratocytes as deep as 300 μm ,²⁸ which may explain why this late haze formation was prevented when CXL was performed the same day after topography-guided PRK in the eyes in the simultaneous group.

With the final reason, we believe it is counterintui-

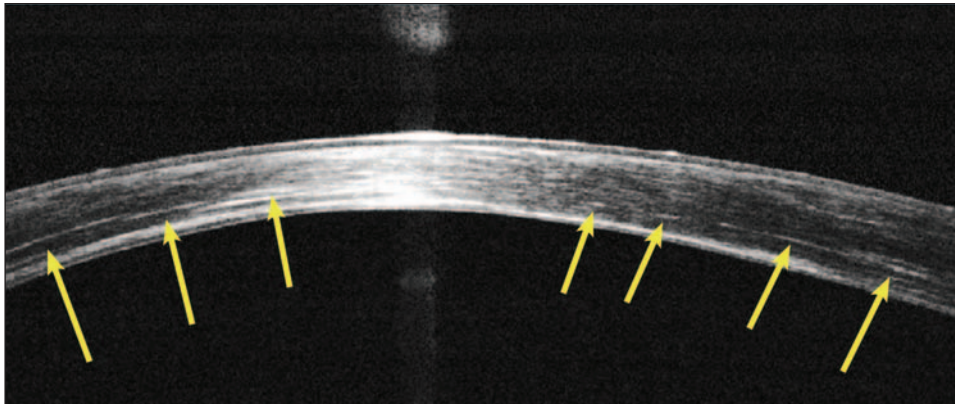


Figure 2. Cornea optical coherence tomography demonstrates hyper-reflective intra-stromal “lines” at 2/3 depth (arrows) corresponding with the clinical presence of the corneal collagen cross-linking (CXL) demarcation line in a patient from the simultaneous group 3 years following the combined topography-guided photorefractive keratectomy and CXL procedure.

tive to remove the cross-linked tissue with topography-guided PRK at a later time, as we are potentially removing a beneficial layer of the stiffer, cross-linked cornea, which helps maintain the normalized corneal shape.

Although a patient with keratoconus can have an improved visual result with the addition of the topography-guided PRK procedure, completely removing a high level of refraction was not our goal. We have placed an arbitrary “ceiling” of 50 μm to the amount of tissue that we safely remove centrally, anticipating that further thinning might destabilize the cornea’s biomechanical integrity, even with the effect of CXL.

Special attention should be given to eyes with a preoperative minimal corneal thickness $<350 \mu\text{m}$ because of potential cytotoxic effects of UVA light on corneal endothelial cells. It should be noted that the proprietary riboflavin solution used was a slightly hypotonic (340 mOsm) formulation, resulting in slight “swelling” of the cornea intraoperatively (during CXL). This restored the corneal thickness to $\sim 400 \mu\text{m}$ to protect the corneal endothelium, and may be the reason we did not encounter any corneal endothelial decompensation in any of the eyes studied.

In addition, the laser treatment was applied with caution, as the refractive effect of the CXL (cornea flattening), had to be anticipated. For this reason, we elected to always attempt a significant undercorrection of both the sphere and cylinder by at least 30%. As described previously, we suggest attempting at most 70% of the measured sphere and cylinder when planning the excimer ablation with T-CAT software or other wavefront-guided software after CXL. In the future, we hope to more accurately determine the new ablation rate of CXL stroma.

Simultaneous topography-guided PRK and CXL appeared in this study to be superior to sequential treatment in the rehabilitation of keratoconus. A possible reason for the difference may be an “enhanced” CXL in the former group, either due to better penetration

of the riboflavin solution through the ablated stroma or to the absence of Bowman’s membrane. In addition, cross-linking the more “normal” corneal shape in the laser pre-treated keratoconus eyes (simultaneous group) makes them more “resistant” to factors affecting ectasia progression.

Why bother with topography-guided PRK in the first place? Our long-term follow-up of CXL alone in keratoconus appears to halt ectasia progression, but it often leaves the patient with the puzzling visual rehabilitation, where spectacles and contact lenses are not effective or tolerable. In the patient population we encounter, the great majority fall into this category even when CXL has successfully halted the progression of ectasia.

The reality of the efficacy of topography-guided PRK and CXL has been the reduction of penetrating keratoplasty cases performed for the indication of keratoconus in our clinical practice over the past 4 years. The same-day, simultaneous topography-guided PRK/CXL procedure was easy to perform, but in some cases the central epithelial surface took up to 1 month to smoothen and become lucent. It took from 1 to 4 weeks for us to detect stable changes in the keratometry and topography, which seemed to match the visual and refractive changes.

A specific demarcation line of separation was noted between the suspected cross-linked collagen and the deeper cornea both clinically²⁹ as well as with corneal OCT (Optivue, Calif) (Fig 2). The cross-linking effect in the stroma was clinically assessed at the slit-lamp following the procedure by the “ground-glass” appearance of the anterior stroma, and in most cases, by the presence of ultra-thin, curved whitish fine lines in the anterior and mid-stroma (Fig 3). These lines do not appear to affect vision and tend to fade away by postoperative month 12. In our clinical assessment, the presence of this finding over the anterior half of stroma confirms sufficient CXL treatment has occurred. As we perform more CXL procedures, we hope to learn which




Figure 3. External cornea clinical picture 6 months postoperatively in a patient from the simultaneous group (same-day, simultaneous topography-guided photorefractive keratectomy and corneal collagen cross-linking [CXL]) demonstrates the multiple fine intrastromal lines attributed by the author to CXL. The cornea haze score in this case was zero.

candidates might best benefit from the procedure.

Questions such as “How much ectasia?” and “What types of ectasia can we safely and predictably correct?” as well as “Is there a minimum preoperative CXL corneal thickness that will not respond to the procedure?” require further investigation. Strategies need to be developed to determine the attempted correction and ablation depth for the topography-guided PRK portion of this process. The proper concentration of riboflavin, its delivery within the corneal stroma, and the proper UVA light exposure and duration will need to be adjusted as we move from animal model studies into clinical procedures. Perhaps CXL will have a wider application as prophylaxis in laser refractive surgery, as we reported in PRK³⁰ and LASIK.³¹

Our findings suggest better results with same-day, simultaneous topography-guided PRK and collagen CXL, as a therapeutic intervention in highly irregular corneas with progressive keratoconus. Our goal was to stabilize the ectasia (with CXL) and rehabilitate the vision (with topography-guided PRK) in young adults with advancing keratoconus to delay or even avoid corneal transplantation. Larger, prospective and randomized, comparative studies, establishing the safety and efficacy of this treatment, and longer follow-up, are necessary to further validate these results.

REFERENCES

1. Krachmer JH, Feder RS, Belin MW. Keratoconus and related noninflammatory corneal thinning disorders. *Surv Ophthalmol.* 1984;28:293-322.
2. Rabinowitz Y. Keratoconus. *Surv Ophthalmol.* 1998;42:297-319.
3. Kanellopoulos AJ, Pe LH, Perry HD, Donnenfeld ED. Modified

intracorneal ring segment implantations (INTACS) for the management of moderate to advanced keratoconus: efficacy and complications. *Cornea.* 2006;25:29-33.

4. Ertan A, Colin J. Intracorneal rings for keratoconus and keratectasia. *J Cataract Refract Surg.* 2007;33:1303-1314.
5. Amayem AF, Anwar M. Fluid lamellar keratoplasty in keratoconus. *Ophthalmology.* 2000;107:76-79.
6. Koralewska-Makár A, Florén I, Stenevi U. The results of penetrating keratoplasty for keratoconus. *Acta Ophthalmol Scand.* 1996;74:187-190.
7. Kanellopoulos AJ, Perry HD, Donnenfeld ED. Visual rehabilitation following penetrating keratoplasty. *Ophthalmology.* 1996;103:142.
8. Doyle SJ, Harper C, Marcyniuk B, Ridgway AE. Prediction of refractive outcome in penetrating keratoplasty for keratoconus. *Cornea.* 1996;15:441-445.
9. Wollensak G, Spoerl E, Seiler T. Stress-strain measurements of human and porcine corneas after riboflavin-ultraviolet-A-induced cross-linking. *J Cataract Refract Surg.* 2003;29:1780-1785.
10. Wollensak G, Spoerl E, Seiler T. Riboflavin/ultraviolet-a-induced collagen crosslinking for the treatment of keratoconus. *Am J Ophthalmol.* 2003;135:620-627.
11. Wollensak G. Crosslinking treatment of progressive keratoconus: new hope. *Curr Opin Ophthalmol.* 2006;17:356-360.
12. Mazzotta C, Balestrazzi A, Traversi C, Baiocchi S, Caporossi T, Tommasi C, Caporossi A. Treatment of progressive keratoconus by riboflavin-UVA-induced cross-linking of corneal collagen: ultrastructural analysis by Heidelberg Retinal Tomograph II in vivo confocal microscopy in humans. *Cornea.* 2007;26:390-397.
13. Braun E, Kanellopoulos J, Pe L, et al. Riboflavin/ultraviolet A-induced collagen cross-linking in the management of keratoconus. *Invest Ophthalmol Vis Sci.* 2005;46:E-Abstract 4964.
14. Barbarino SC, Papakostas AD, Sperber L, Jue AT, Park L, Kanellopoulos J. Post-LASIK ectasia: stabilization and effective management with riboflavin/ultraviolet A-Induced collagen cross-linking. *Invest Ophthalmol Vis Sci.* 2006;47:E-Abstract 536.
15. Spoerl E, Mrochen M, Sliney D, Trokel S, Seiler T. Safety of UVA-riboflavin cross-linking of the cornea. *Cornea.* 2007;26:385-389.
16. Spoerl E, Huhle M, Seiler T. Induction of cross-links in corneal tissue. *Exp Eye Res.* 1998;66:97-103.
17. Hafezi F, Kanellopoulos J, Wiltfang R, Seiler T. Corneal collagen crosslinking with riboflavin and ultraviolet A to treat induced keratectasia after laser in situ keratomileusis. *J Cataract Refract Surg.* 2007;33: 2035-2040.
18. Wong JJ, Papakostas AD, Kanellopoulos AJ, Sperber LT. Post-LASIK ectasia: PRK following previous stabilization and effective management with riboflavin/ultraviolet A-induced collagen cross-linking. *Invest Ophthalmol Vis Sci.* 2006;47:E-Abstract 557.
19. Lai EC, Kanellopoulos AJ. Keratoconus management: riboflavin/ultraviolet A-induced collagen cross-linking followed by surface excimer ablation. *Invest Ophthalmol Vis Sci.* 2007;48: E-Abstract 5324.
20. Kanellopoulos AJ. Post-LASIK ectasia. *Ophthalmology.* 2007;114:1230
21. Kanellopoulos AJ, Binder PS. Collagen cross-linking (CCL) with sequential topography-guided PRK. A temporizing alternative for keratoconus to penetrating keratoplasty. *Cornea.* 2007;26:891-895.
22. Ewald M, Kanellopoulos J. Limited topography-guided surface ablation (TGSA) followed by stabilization with collagen cross-linking with UV irradiation and riboflavin (UVACXL) for keratoconus (KC). *Invest Ophthalmol Vis Sci.* 2008;49:E-Abstract 4338.

Sequential vs Simultaneous Topography-guided PRK and CXL/Kanellopoulos

23. Lustig MJ, Kanellopoulos A. Topography-guided retreatment in 11 symptomatic eyes following LASIK. *Invest Ophthalmol Vis Sci.* 2004;45:E-Abstract 285.
24. Ledoux DM, Kanellopoulos A. Topography-guided LASIK, early experience in 7 irregular eyes. *Invest Ophthalmol Vis Sci.* 2004;45:E-Abstract 2821.
25. Kanellopoulos AJ. Topography-guided custom retreatments in 27 symptomatic eyes. *J Refract Surg.* 2005;21:S513-S518.
26. Kanellopoulos AJ. Managing highly distorted corneas with topography-guided treatment. In: *ISRS/AAO 2007 Subspecialty Day/Refractive Surgery Syllabus. Section II: Ablation Strategies.* San Francisco, Calif: American Academy of Ophthalmology; 2007:13-15.
27. Xu H, Liu S, Xia X, Huang P, Wang P, Wu X. Mitomycin C reduces haze formation in rabbits after excimer laser photorefractive keratectomy. *J Refract Surg.* 2001;17:342-349.
28. Wollensak G, Spoerl E, Reber F, Seiler T. Keratocyte cytotoxicity of riboflavin/UVA treatment in vitro. *Eye.* 2004;18:718-722.
29. Seiler T, Hafezi F. Corneal cross-linking-induced stromal demarcation line. *Cornea.* 2006;25:1057-1059.
30. Kanellopoulos AJ. Safety and efficacy of prophylactic, ultraviolet A irradiation cross-linking for high-risk myopic PRK cases. Poster presentation at: ISRS/AAO Refractive Surgery Subspecialty Day American Academy of Ophthalmology annual meeting; November 7, 2008; Atlanta, Ga.
31. Kanellopoulos AJ. Prophylactic, ultraviolet A cross-linking combined at the completion of high risk myopic LASIK cases. Presented at: ISRS/AAO Refractive Surgery Subspecialty Day American Academy of Ophthalmology annual meeting; November 8, 2008; Atlanta, Ga.