

LASIK for Hyperopia With the WaveLight Excimer Laser

A. John Kanellopoulos, MD; Joseph Conway, MD; Lawrence H. Pe, MD

ABSTRACT

PURPOSE: To evaluate the safety and efficacy of the ALLEGRETTO WAVE excimer laser system (WaveLight Laser Technologie AG, Erlangen, Germany) in LASIK for hyperopia and hyperopic astigmatism.

METHODS: One hundred twenty consecutive LASIK cases for hyperopia with or without astigmatism treated with the ALLEGRETTO WAVE excimer laser were prospectively evaluated up to 12 months postoperatively. Patients were allocated into three groups according to their refractive sphere and cylinder: a low hyperopia group, with up to +3.00 diopters (D) sphere and astigmatism $\leq +1.00$ D (n=52); a moderate hyperopia group with +3.25 to +5.00 D sphere and astigmatism of $\leq +1.00$ D (n=45); and a high hyperopia/toric group sphere $\geq +5.25$ D or cylinder ≥ 1.25 D (n=23). Flaps were created with the Moria M2 microkeratome (Moria, Antony, France). Parameters evaluated were pre- and postoperative refractive error, uncorrected visual acuity, best spectacle-corrected visual acuity (BSCVA), higher order aberration change, and contrast sensitivity.

RESULTS: One hundred twelve eyes (93%) were available for follow-up at 12 months. Of the eyes in the low hyperopia group, 92% were within ± 0.50 D of the refractive goal. For the moderate sphere group and the high hyperopia/toric group, 79% and 71% of eyes, respectively, were within ± 0.50 D of the refractive goal. No eye lost ≥ 2 lines of BSCVA. An increase in higher order aberrations was noted in the high hyperopia/toric group from $0.47 \mu\text{m}$ (± 0.096) to $0.94 \mu\text{m}$ (± 0.0167) ($P < .001$). No significant changes in higher order aberrations were noted in the low and moderate hyperopia groups.

CONCLUSIONS: Hyperopic LASIK using the WaveLight ALLEGRETTO WAVE excimer laser appears to be safe and effective in the correction of low, moderate, and high hyperopia and hyperopic astigmatism. [J Refract Surg. 2006;22:xx-xx.]

Flying spot lasers have enhanced the safety and efficacy of hyperopic and astigmatic corrections with LASIK over the past several years.¹⁻⁸ In this study, we evaluated the safety and efficacy of the ALLEGRETTO WAVE excimer laser system (WaveLight Laser Technologie AG, Erlangen, Germany) and the Moria M2 microkeratome (Moria SE, Antony, France) in our LASIK clinical practice for hyperopia with or without astigmatism. Subsequent to our study, the WaveLight technology gained Food and Drug Administration (FDA) approval in the United States for use in hyperopia and hyperopic astigmatism.⁹

MATERIALS AND METHODS

One hundred twenty consecutive eyes of 64 patients underwent LASIK for hyperopia or hyperopic astigmatism. The inclusion criteria were hyperopic sphere up to +6.00 diopters (D) and astigmatism up to 5.00 D, with a maximum spherical equivalent refraction of +6.00 D. Patients aged < 18 years and those with a history of corneal surgery, herpetic eye disease, corneal dystrophy, corneal scarring, keratoconus, severe dry eye, and collagen vascular diseases were excluded from this study.

Preoperative evaluation included uncorrected visual acuity (UCVA), refraction (manifest and cycloplegic), best spectacle-corrected visual acuity (BSCVA), slit-lamp examination, fundus evaluation, corneal topographies with the Orbscan II (Bausch & Lomb, Rochester, NY) and the ALLEGRETTO WAVE

From the Department of Ophthalmology, Manhattan Eye, Ear and Throat Hospital, New York, NY (Kanellopoulos, Conway, Pe); the Department of Ophthalmology, New York University Medical School, New York, NY (Kanellopoulos, Conway, Pe); and LaserVision.gr Institute, Athens, Greece (Kanellopoulos, Pe).

Presented in part as a poster at the Association for Research in Vision and Ophthalmology Annual Meeting; May 4-9, 2003; Ft Lauderdale, Fla.

Presented in part as a paper at the European Society of Cataract and Refractive Surgeons Annual Meeting; September 6-10, 2003; Munich, Germany.

The authors have no financial interests in the materials presented herein.

Correspondence: A. John Kanellopoulos, MD, LaserVision.gr Institute, Pyrgos Athinon, Mesogeion 2 & Vasilissis Sofias, Ampelokipi, 11527, Athens, Greece. Tel: 30 210 7472 777; Fax 30 210 7472 789; E-mail: laservision@internet.gr

Received: June 4, 2004

Accepted: March 23, 2005

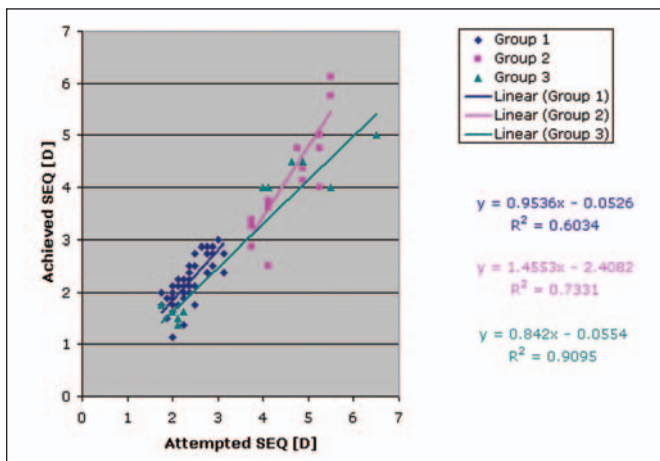


Figure 1. Scattergram of preoperative and 1-year postoperative manifest spherical equivalent refraction (SEQ) in each group. The blue, pink, and green axes represent the attempted correction—each spot above the axis represents an undercorrection, each spot below the axis represents an overcorrection.

Topolyzer (Oculus, Wetzlar, Germany), ultrasound corneal pachymetry with the NIDEK US-1800 (Echoscan; NIDEK, Aichi, Japan), and wavefront analysis with the ALLEGRO WAVE Analyzer (WaveLight Laser Technologie AG) measured at a 6.5-mm pupil size. Contrast sensitivity was also measured at 12 cycles/degree using the CSV-1000 contrast sensitivity chart (VectorVision, Arcanum, Ohio).

Our initial pilot experience with 30 eyes led to using a custom nomogram adjustment algorithm for the ablation treatment plan. This was used to compensate for the regression and undercorrection we encountered in the earlier cases.

The procedures were carried out under topical anesthesia with a drop of proparacaine 1% (Alcaine; Alcon, Ft Worth, Tex) instilled into the patient's eye just before the procedure. Eyelids were cleaned with povidone iodine antiseptic 10% (Betadine; Purdue Pharma L.P., Stamford, Conn) and the eyelashes were isolated with sterile plastic drapes (Tegaderm; 3M Health Care, St Paul, Minn). The Moria M2 microkeratome was used to cut the corneal flaps in all cases. The flaps were cut to expose a stromal bed of at least 9.0 mm in diameter to accommodate hyperopic (large diameter) ablations.

The ALLEGRETTO WAVE excimer laser was used to perform the ablations in all cases. These were all standard non-wavefront-guided ablations. We targeted to correct the cycloplegic refraction for emmetropia in all cases. The ALLEGRETTO WAVE excimer laser is a flying spot laser system; it works with a 0.95-mm Gaussian spot and fires at a rate of 200 Hz. The laser works in conjunction with a 250-Hz video-based infrared tracking system to compensate for any eye move-

ment, making it even more precise in performing tissue ablation. To standardize the procedure, all optical zones were set at 6.5 mm in all cases. Together with the transition, the total ablation zone was 9.0 mm.

The spherical corrections were achieved by ablating an annular zone of tissue in the mid-peripheral cornea, making the central cornea steeper. The cylindrical refractive error was corrected in a similar manner by ablating the mid-peripheral zone of the flat meridian.

Patients were examined 30 minutes postoperatively to check for any flap irregularities or complications. Patients were seen at regular postoperative intervals at 1 month, 3 months, 6 months, and 12 months, with the manifest refraction repeated each time. At 12-month follow-up, wavefront and contrast sensitivity were repeated.

All surgeries were performed by a single surgeon (A.J.K.) in an outpatient refractive surgery clinic in Athens, Greece. Measurements and data were obtained by the surgeon and his staff. Preoperative patient demographic and clinical data can be found in the Table.

Patients were divided into three groups for purposes of data analysis. The first group was the low hyperopia group defined as eyes with hyperopia of up to +3.00 D and astigmatism $\leq +1.00$ D. The second group was the moderate hyperopia group with hyperopia from +3.25 to +5.00 D and astigmatism $\leq +1.00$ D. The third group was the high hyperopia/toric group, which included eyes with hyperopia of at least +5.25 D and/or eyes with cylinder $\geq +1.25$ D. The low hyperopia group had 52 eyes, the moderate hyperopia group had 45 eyes, and the high hyperopia/toric group had 23 eyes.

The data were statistically compared using paired Student *t* test, Pearson's correlation, and Wilcoxon signed rank test.

RESULTS

One hundred twelve eyes (93%) (58 patients) of the initial 120 eyes were available for follow-up 12 months postoperatively; 8 eyes (6 patients) were lost to follow-up. The predictability plots (cumulative attempted vs achieved) are shown in Figure 1. In the low hyperopia group, 92% of eyes were within ± 0.50 D of the refractive goal, 79% of eyes in the moderate hyperopia group were within ± 0.50 D of the refractive goal, and 71% of eyes in the high hyperopia/toric group were within ± 0.50 D of the refractive goal. Six eyes (3 patients) in the high hyperopia/toric group were undercorrected. A summary of postoperative data is shown in the Table. Uncorrected visual acuity is also summarized in the Table and the overall change in UCVA is shown in Figure 2.

A small but significant (Wilcoxon signed rank test, $P=.02$) increase was noted in the mean BSCVA for the

TABLE
**Clinical Data for Eyes That Received LASIK for
 Hyperopia or Hyperopic Astigmatism**

	Low Hyperopia Group		Moderate Hyperopia Group		High/Toric Hyperopia Group	
	Preop	1-Year Postop	Preop	1-Year Postop	Preop	1-Year Postop
No. eyes	52	49	45	42	23	21
No. eyes within ± 0.50 D (%)	0 (0)	45 (92)	0 (0)	33 (79)	0 (0)	15 (71)
Sphere (D) (range)	2.18 ± 0.36 (1.50 to 2.75)	$0.10 \pm 0.27^*$ (-0.25 to 0.75)	4.57 ± 0.69 (3.50 to 5.50)	$0.16 \pm 0.58^*$ (0.00 to 1.50)	2.24 ± 1.18 (0.25 to 6.50)	$0.25 \pm 0.68^*$ (-0.75 to 1.50)
Cylinder (D) (range)	0.40 ± 0.29 (0.00 to 1.00)	$0.13 \pm 0.13^*$ (0.00 to 0.25)	0.42 ± 0.33 (0.00 to 1.00)	$0.14 \pm 0.28^*$ (-0.25 to 0.75)	2.83 ± 1.32 (0.00 to 4.00)	$0.25 \pm 0.68^*$ (0.00 to 2.75)
SEQ (D) (range)	2.38 ± 0.37 (1.75 to 3.13)	0.16 ± 0.28 (-0.25 to 0.88)	4.78 ± 0.63 (3.75 to 5.50)	$0.23 \pm 0.63^*$ (-0.33 to 1.63)	3.43 ± 1.64 (1.75 to 4.00)	$0.69 \pm 0.92^*$ (0.00 to 1.50)
UCVA (SD)	20/85 (± 0.07)	20/21 (± 0.11) [*]	20/100 (± 0.25)	20/25 (± 0.17) [*]	10/100 (± 0.07)	20/33 (± 0.51) [*]
BSCVA (SD)	20/20 (± 0.06)	20/20 (± 0.08) [†]	20/23 (± 0.18)	20/22 (± 0.17) [†]	20/31 (± 0.18)	20/22 (± 0.17) [*]
Contrast sensitivity	5.35 ± 0.66	5.16 ± 0.66 [†]	4.87 ± 0.83	$3.86 \pm 0.87^*$	4.86 ± 0.65	$3.05 \pm 0.79^*$
Root-mean-square (SD)	$0.42 (\pm 0.0380)$	$0.62 (\pm 0.119)^*$	$0.43 (\pm 0.044)$	$0.50 (0.070)^*$	$0.47 (\pm 0.096)$	$0.94 (\pm 0.167)^*$

SEQ = spherical equivalent, UCVA = uncorrected visual acuity, BSCVA = best spectacle-corrected visual acuity

* $P < .001$

[†] $P < .05$

population, which may be attributed to the improvement in the high hyperopia/toric group. In this group, the BSCVA improved from 20/31 (standard deviation [SD] ± 0.915) to 20/22 (SD ± 0.174) ($P < .001$). In the low and moderate hyperopia groups, the change was not statistically significant—20/21 (SD ± 0.055) to 20/20 (SD ± 1.01) and 20/22 (SD ± 0.179) remained at 20/22 (SD ± 0.157), respectively.

No eye lost ≥ 2 lines of BSCVA. In the high hyperopia group, two eyes lost one line of BSCVA. No BSCVA loss was noted in the low and moderate hyperopia groups.

The change in BSCVA was not statistically significant in the low hyperopia group (Wilcoxon signed ranks test, $P = .33$), but was in the moderate hyperopia group and the high hyperopia/toric group (Wilcoxon signed rank test, $P < .001$ and $P < .001$, respectively).

The higher order aberrations as measured by the root-mean-square increased by 46% from a preoperative mean of 0.43 (SD ± 0.058) to a mean of 0.63 (SD ± 0.198), which was significant for all three groups (paired Student t test, $P < .001$). The increase was largest in the high hyperopia/toric group from 0.47 (SD ± 0.096) to 0.94 (SD ± 0.167) (101%). In the low hyperopia group, the change increased by 46% from 0.42 (SD ± 0.380) to 0.62 (SD ± 0.119). The least amount of change (15%) occurred in the moderate hyperopia group from 0.43 (SD ± 0.044) to 0.50 (SD ± 0.070).

A significant inverse correlation (Pearson's correlation, $P = .01$) was noted between the postoperative higher order aberration and the postoperative contrast sensitivity score.

From 1 month to 3 months, there was a mean change in manifest refraction of +0.25 D (SD ± 0.06) for the low hyperopia group, +0.24 D (SD ± 0.09) for the moderate hyperopia group, and +0.40 D (SD ± 0.08) for the high/hyperopia toric group. From 3 months to 12 months, the change in refraction was small and not significant in all three groups (Fig 3).

One case from the high hyperopia/toric group required flap lift and debridement for significant epithelial ingrowth within the flap interface 2 months postoperatively. This case was followed with the rest of the group for the duration of the study.

No significant complications were noted in this limited group.

DISCUSSION

Broad beam scanning excimer lasers for correction of hyperopic refractive errors have been moderately satisfactory.¹⁰ Unlike in myopia where corneal flattening corrects the refractive error, in hyperopia and mixed astigmatism, central corneal steepening is needed to compensate for the refractive error. This can only be achieved by ablating corneal tissue mid-peripherally

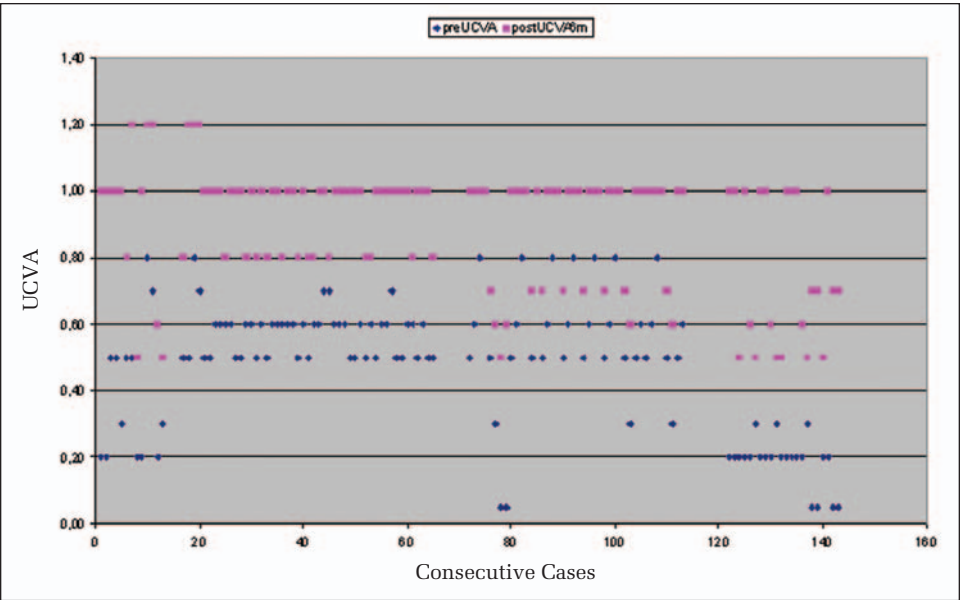


Figure 2. Cumulative graph representing the overall UCVA change (in decimal, 1.0 = 20/20) at 1 year following hyperopic LASIK. For each case, the blue dot represents the preoperative UCVA and the pink dot the postoperative UCVA.

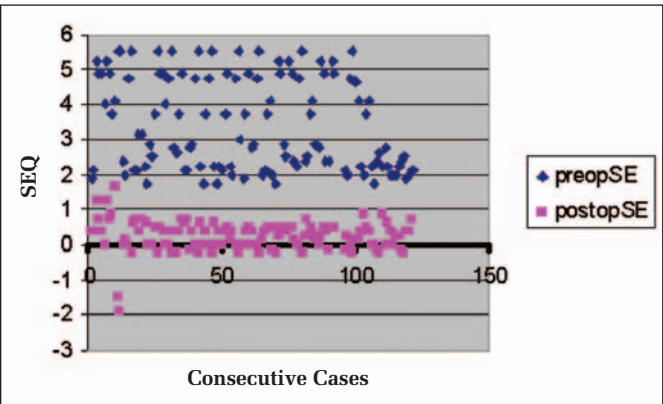


Figure 3. This chart illustrates the overall spherical equivalent refraction (SEQ) following hyperopic LASIK. For each case, the blue dot represents preoperative spherical equivalent refraction and the pink dot represents postoperative spherical equivalent refraction at 1 year.

and leaving tissue centrally, which was a challenging task with broad beam excimer systems that were controlled by aperture mechanisms. With the advent of flying spot lasers, it may be possible to overcome this limitation. These lasers can accurately ablate the cornea into more complex shapes compared to the older scanning systems. Thus, hyperopic and mixed astigmatism ablation patterns are theoretically more efficient with these lasers.

We have shown in this case series that the ALLEGRETTO WAVE system can safely and effectively perform low, moderate, and high hyperopic and hyperopic astigmatic corrections, which is comparable to the results we obtained when performing myopic corrections (unpublished data 2002).

We chose to adopt the grouping of low, moderate, and high hyperopia based on a review of the published

literature in LASIK hyperopic corrections¹¹ and on our earlier experience with previous technologies, prior to the use of the ALLEGRETTO WAVE. We currently use this platform to treat most patients with hyperopia and mixed astigmatism without this classification in mind.

In this study, we used the Moria M2 microkeratome to cut the flaps. Four suction rings were available, allowing the surgeon to customize the flap diameter depending on the preoperative keratometry readings according to the manufacturer nomogram. This feature of the M2 is valuable because it allows the flap to be cut on a wide variety of corneal curvatures (flat to steep), and mostly flatter corneal curvatures in hyperopes. An intricacy of hyperopic LASIK that we encountered is the inadequacy of flap diameters and the difficulty of ablation centration. We aimed for slight (0.5 to 0.7 mm) decentration towards the hinge side to avoid hinge placement within the ablation zone. We also calculated the shortest flap diameter to be at least 9.0 mm, to be sufficient for the ablation placement. We did not use hinge protectors, as the flap was folded onto itself and its most distant epithelial surface served as protection of the hinge from inadvertent ablation.

Some authors have expressed concern about inducing higher order aberrations and induced astigmatism with hyperopic LASIK ablations.^{4,5} In this group, we observed an overall increase in root-mean-square by 46%. Despite this, there was a mean gain in BSCVA for the population possibly from the efficient correction of astigmatism. The increase of high order aberrations may be due to the irregular/small functioning optical zone, induced irregular astigmatism of flap creation, iatrogenic dry eye, the ablation itself, and other

secondary changes that result from altering the natural shape of the cornea.^{12,13}

A slight increase of 0.4 lines in BSCVA was noted; however, this is not expected in hyperopic treatments because correcting hyperopia in the cornea plane induces some “minification” effect as compared to the patient’s spectacle correction. The improvement, although small, was statistically significant for all groups. This is consistent with the results obtained in the FDA clinical trials, where overall gain of 0.3 lines was reported. The improvement was most notable in the high hyperopia/toric group, which may be partly explained by the correction of the astigmatism at the corneal plane.

At 12-month follow-up, 92% of low hyperopic eyes, 79% of moderate hyperopic eyes, and 69% of high hyperopic eyes were within 0.50 D of the intended postoperative refraction, which was comparable to the predictability manifest refractive spherical equivalent (MRSE) in the US FDA trials at 6 months: mean MRSE +0.24 D (± 0.54) with 70% of eyes within 0.50 D of the refractive target. These results are better or at least similar to published results achieved with other systems for the correction of hyperopic refractive errors.^{1-8,11} This efficacy also extends to the treatment of mixed hyperopic and astigmatic refractive errors. We theorize that these good results may be explained, at least in part, by the fact that the system transposes the refractive error into positive cylinder and the treatment of the astigmatism takes place on the flat meridian, ie, the laser ablates tissue peripherally, making the center steeper. This principle leaves the central optical zone in these treatments untreated by the excimer as both the hyperopia and cylinder are treated in the theoretical peripheral ring of 6.5 to 9.5 mm from the center of the visual axis. This principle along with, in our opinion, the smooth stromal surface created by the microkeratome may contribute to the rapid visual recovery noted at day one in this limited case series.

Laser in situ keratomileusis using the ALLEGRETTO WAVE excimer laser and the Moria M2 microkeratome appears to be safe and effective in the correction of low, moderate, and high hyperopia and hyperopic astigmatism in all three groups evaluated. The postoperative results at 1 year are notable for hyperopic and astigmatic refractive error correction and improvement in UCVA and BSCVA, with minimal regression and need for enhancement.

We consider our 1-year follow-up to be short, as our clinical experience has shown late hyperopic regression in previous LASIK cases, a measurement we were not able to include in this series. Larger and longer follow-up studies will better elucidate the safety, efficacy, and stability of this surgical intervention.

REFERENCES

1. Salz JJ, Stevens CA, LADARVision LASIK Hyperopia Study Group. LASIK correction of spherical hyperopia, hyperopic astigmatism, and mixed astigmatism with the LADARVision excimer laser system. *Ophthalmology*. 2002;109:1647-1656.
2. Lian J, Ye W, Zhou D, Wang K. Laser in situ keratomileusis for correction of hyperopia and hyperopic astigmatism with the Technolas 117C. *J Refract Surg*. 2002;18:435-438.
3. Carones F, Vigo L, Scandola E. Laser in situ keratomileusis for hyperopia and hyperopic and mixed astigmatism with LADARVision using 7 to 10-mm ablation diameters. *J Refract Surg*. 2003;19:548-554.
4. El-Agha MS, Bowman RW, Cavanagh D, McCulley JP. Comparison of photorefractive keratectomy and laser in situ keratomileusis for the treatment of compound hyperopic astigmatism. *J Cataract Refract Surg*. 2003;29:900-907.
5. Pineda-Fernandez A, Rueda L, Huang D, Nur J, Jaramillo J. Laser in situ keratomileusis for hyperopia and hyperopic astigmatism with the Nidek EC-5000 excimer laser. *J Refract Surg*. 2001;17:670-675.
6. Ditzel K, Fiedler J, Pieger S. Laser in situ keratomileusis for hyperopia and hyperopic astigmatism using the Meditec MEL 70 spot scanner. *J Refract Surg*. 2002;18:430-434.
7. Wygledowska-Promienska D, Zawojka I, Gierek-Ciaciura S. New generation of excimer laser—Asclepion Meditec MEL 70 G Scan [Polish]. *Klin Oczna*. 2000;102:373-375.
8. Sciscio A, Hull CC, Stephenson CG, Baldwin H, O’Brart D, Marshall J. Fourier analysis of induced irregular astigmatism. Photorefractive keratectomy versus laser in situ keratomileusis in a bilateral cohort of hyperopic patients. *J Cataract Refract Surg*. 2003;29:1709-1717.
9. FDA clinical trials, WaveLight ALLEGRETTO WAVE Excimer Laser System - P030008USFDA. <http://www.fda.gov/cdrh/PDF3/p030008.html>. Accessed NEED DATE.
10. Daush D, Landes M. The Aesculap-Meditec laser: results from Germany. Laser correction for hyperopia. In: Salz JJ, McDonnell PJ, McDonald MB, eds. *Corneal Laser Surgery*. St Louis, Mo: Mosby; 1995:237-254.
11. Arbelaez MC, Knorz MC. Laser in situ keratomileusis for hyperopia and hyperopic astigmatism. *J Refract Surg*. 1999;15:406-414.
12. Wang L, Koch DD. Anterior corneal optical aberrations induced by laser in situ keratomileusis for hyperopia. *J Cataract Refract Surg*. 2003;29:1702-1708.
13. Oshika T, Klyce SD, Applegate RA, Howland HC, El Danasoury MA. Comparison of corneal wavefront aberrations after photorefractive keratectomy and laser in situ keratomileusis. *Am J Ophthalmol*. 1999;127:1-7.