

Cataract & Refractive Surgery TODAY


 October 2003



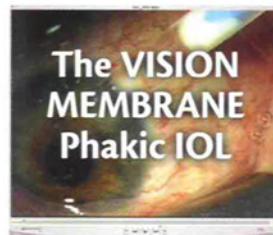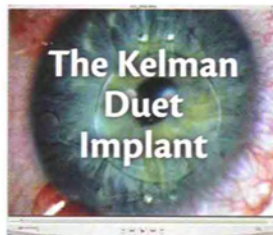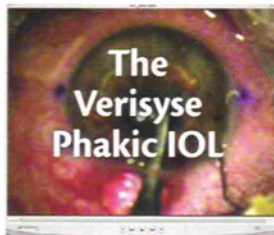
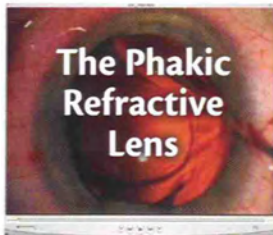
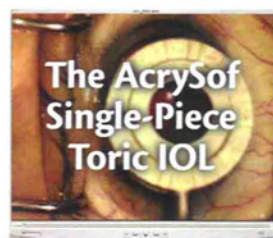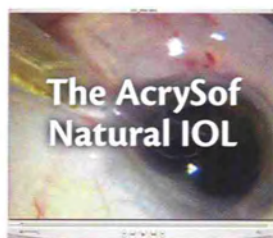
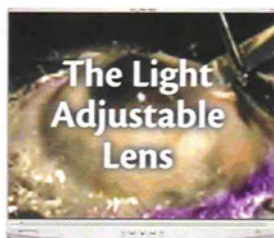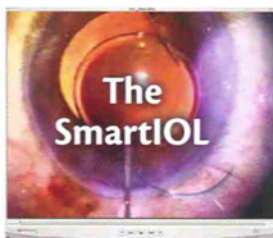Educational CD-ROM Included!

New Lens Technologies in Action

COME VISIT
CATARACT & REFRACTIVE
SURGERY TODAY
BOOTH #2690



An interactive guide to implanting novel IOLs.



Presorted Standard
U.S. Postage
Paid
Harrisburg, PA
Permit 1113

Wavefront-Guided Enhancements

Improving higher-order aberrations and contrast sensitivity in symptomatic post-LASIK eyes.

BY A. JOHN KANELLOPOULOS, MD

I recently participated in a multicenter study designed to evaluate the safety and efficacy of wavefront-guided LASIK enhancements using the Allegretto Wave system (WaveLight Technologie AG, Erlangen, Germany) for symptomatic post-LASIK eyes. The other investigators and I have extensive experience using this system for standard and wavefront-guided primary LASIK, and we have presented these findings during the last 2 years. WaveLight Technologie AG organized the current study in order to elucidate further the ability of its wavefront analyzer and of wavefront-guided treatments with its excimer laser to correct aberrations in post-LASIK patients.

SUBJECTS

One inclusion criterion was myopia, hyperopia, or mixed astigmatism with a refractive error within ± 1.50 D (spherical equivalent). Additionally, the diameter of wavefront-guided laser treatment had to be greater than or equal to 6 mm with an RMSH value (measurement of total higher-order aberrations) of at least 0.4 μm when measured by the wavefront analyzer at a 6-mm pupil diameter. Subjects had to present with at least one of the following five clinical indications: (1) small, original optical zone; (2) decentered ablation; (3) irregular astigmatism; (4) night vision problems; and (5) under- or over-correction. An additional criterion for study inclusion was our ability to obtain four highly reproducible, higher-order-aberration maps that had a diameter of at least 6 mm after the eye had been dilated with a single drop of tropicamide 1% but undergone no cycloplegia.

METHODOLOGY

The study was conducted at four individual centers by investigators Theo Seiler, MD, PhD, and Michael Mrochen, PhD, at the University of Zurich in Switzerland; Arthur Cummings, MD, at a center in Dublin, Ireland;

Matthias Maus, MD, at a center in Cologne, Germany; and me at the Laservision Eye Institute in Athens, Greece. Joachim Loeffler, a consultant for WaveLight Technologie AG, coordinated the study.

Preoperative evaluations of each subject included UCVA, BCVA with manifest refraction, cycloplegic refraction, measurements of scotopic pupil size (Colvard Pupillometer; OASIS Medical, Inc., Glendora, CA), topography, and simulated Ks calculated with both the Orbscan topographer (Bausch & Lomb, Rochester, NY) and the Allegretto Wave system's topolyzer. When performing measurements with the Allegretto Wave system's wavefront analyzer, we strictly adhered to the study's requirements on diameter. We obtained pachymetry readings by means of both ultrasound and the Orbscan topographer. The data for the operative record included the targeted postoperative refraction.

The Allegretto Wave system's wavefront analyzer averaged together four highly reproducible maps of each subject's higher-order aberrations and used this information for

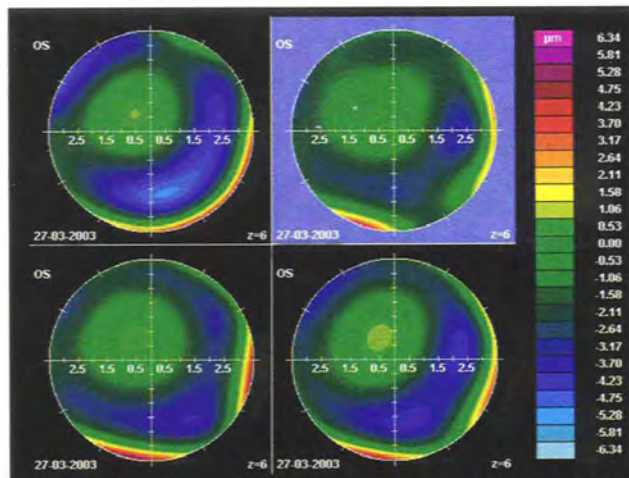


Figure 1. The author obtained higher-order aberration maps of an unhappy post-LASIK patient's left eye.

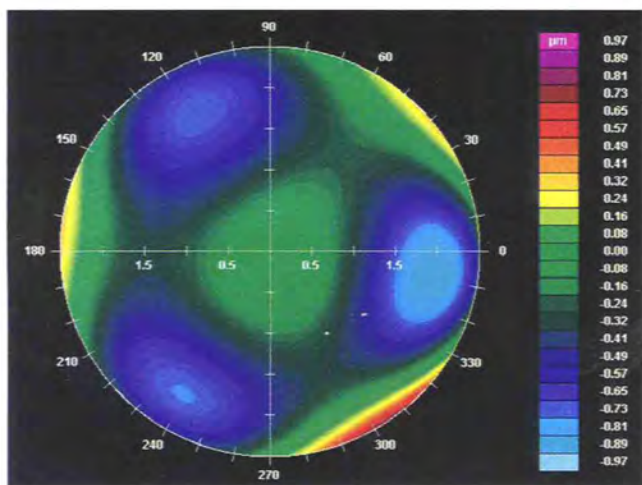


Figure 2. This higher-order aberration map shows the results of a wavefront-guided enhancement procedure on a 6.5-mm optical zone. The RMSH value decreased from 0.75 to 0.23 mm, the patient's low contrast sensitivity improved 150%, and he gained three lines of BCVA in addition to improving subjectively.

the laser treatments. We could only alter the wavefront treatment's diameter, which had to be between 6 and 7 mm, and the amount of the sphere corrected. The system's software currently does not allow manual changes in the amount and axis of astigmatism, because the averaged higher-order aberration maps predetermine this information.

All cases involved lifting (but never cutting) the original LASIK flap, at which time we measured the flap's diameter and thickness. We obtained pachymetry measurements preoperatively, after lifting the flap, and intraoperatively, and we calculated the flap thickness by subtraction pachymetry. We measured the subjects' contrast sensitivity under mesopic conditions and using low-contrast materials, measured their glare preoperatively by means of the CSV-1000 (VectorVision, Arcanum, OH), and noted any intraoperative complications on subjects' charts.

Postoperatively, we recorded each subject's UCVA, manifest refraction, cycloplegic refraction, low contrast sensitivity, topography (calculated with both the Allegretto Wave system's topolyzer and Orbscan topographer), wavefront measurements, and postoperative complications (if any).

RESULTS

The study included 22 eyes of the 26 patients we evaluated, all of whom were symptomatic with either night vision problems or mesopic and photopic ghosting. One of the four patients excluded did not possess the amount of residual corneal thickness necessary for retreatment (we generally required a total corneal reserve of 400 μm and a total stromal bed reserve of $\geq 260 \mu\text{m}$). We excluded three other

patients because of our inability to obtain reproducible wavefront maps and our subsequent decision not to proceed with wavefront-guided treatment for these subjects.

The follow-up period averaged 4 months (ranging from 3 to 7 months). Of the 22 eyes included, the average preoperative amount of sphere was -0.92 D (ranging from plano to -1.50 D), and the mean amount of cylinder was -0.85 D (ranging from 0 to -1.75 D). The mean preoperative BCVA was 20/25, and this figure improved to a mean of 20/18 postoperatively. Not only did none of the patients lose any lines of BCVA, all patients gained at least one line and a maximum of three lines of BCVA. The total amount of higher-order aberrations, as measured by the parameter RMSH, decreased from an average of 0.62 to 0.25 mm. Also, patients experienced a mean improvement in low contrast sensitivity of 55% (Figures 1 and 2).

CONCLUSION

Although my fellow investigators and I found the pre- and postoperative measurement process to be laborious, we determined the enhancement procedure to be easy overall. The real reward of our work has been our patients' extremely high level of satisfaction, owing to the improvement in their visual symptoms. With regard to quality of night vision, I should note that, according to patients' subjective responses, 21 of the 22 eyes corrected had significantly improved, and one had improved mildly. Wavefront measurements and our measurements of these patients' low contrast sensitivities indicated significant clinical improvement in all eyes. None of the patients demonstrated the need for further enhancement during the study's brief follow-up period.

My fellow investigators and I feel that these results strongly suggest that wavefront-guided LASIK retreatment with the Allegretto Wave system appears to be safe and effective for the correction of residual refractive error, and we attribute the enhancement of visual function to the significant improvement of subjects' higher-order aberrations and low contrast sensitivity. We have found that the Allegretto Wave system's wavefront analyzer and excimer laser enabled us to predictably measure and treat most symptomatic post-LASIK patients. ■

A. John Kanellopoulos, MD, is a corneal and refractive surgery specialist. Dr. Kanellopoulos is Director of Laservision.gr Eye Institute in Athens, Greece, and is Clinical Associate Professor of Ophthalmology at New York University Medical School in New York. He holds no financial interest in any of the products mentioned herein. Dr. Kanellopoulos may be reached at +30 21 07 47 27 77; laservision@internet.gr.

