

Review of REFRACTIVE SURGERY

www.reviewofrefrativesurgery.com

VOLUME 4, NUMBER 1

FEBRUARY 2003

Making the Flap *...Technologies and Issues*

Supplement to
REVIEW
of Ophthalmology

Wavefront-guided LASIK TREATS Decentered Ablations

A

A. John Kanellopoulos, MD
Michael Mrochen, PhD

ablation decentration is a troublesome complication following laser in situ keratomileusis and can pose serious visually debilitating side-effects.^{1,3} Causes include intraoperative fixation error and/or drift of the patients' fixation; eccentrically displaced treatment due to surgeon error or equipment calibration error; and eye tracker or eye tracker calibration error.⁴ Larger decentrations are usually associated with larger reductions in low contrast sensitivity and visual acuity.⁵ (Figure 1)

Centration is an equally important bias in measurements as well as reference points in laser treatments. The actual clinical measurements of wavefront with Allegretto flying spot laser (Wavelight, Erlagen, Germany) are centered by the coaxially cited corneal reflex, the geometrical center of the cornea, the corneal apex, and the entrance pupil. (Figure 2)

Centration errors

Decentered ablations are likely to increase higher order aberrations, so it is critical to have a well-centered ablation. To achieve this, patients need to fixate on the target and the alignment of the device relative to the patient's eye must be correct. (Figure 2)

There are two types of centration errors: systematic centration errors, which cause a constant decentration, and random or dynamic centration errors, which causes a smearing of the ablation. The systematic centration errors are caused in different axes. Axes are defined as coordinate systems defined in measurement and treatment. Systematic centration errors can occur when the coordinate system is not stable, the eye tracker is calibrated imprecisely, there is head tilt, or the initial alignment by the operator is not precise, or there is a patient fixation problem. These errors can be avoided with precise alignment techniques.

Random or dynamic centration errors are avoided mainly with active eye track-

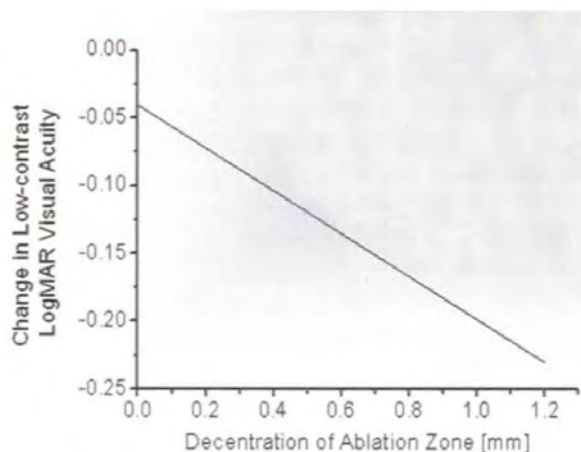
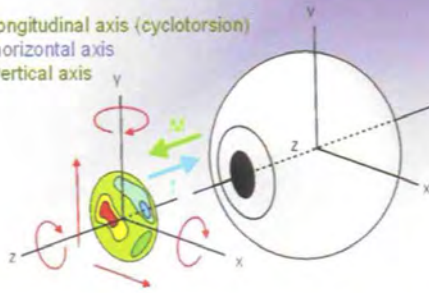


Figure 1. The change in visual acuity under low contrast situations compared to the decentration of the ablation zone in mm. Verdon et al, Visual performance after photorefractive keratectomy, 1996

Centration: a task with 5 degrees of freedom

- Horizontal shifts
- Vertical shifts
- Rotation around longitudinal axis (cyclotorsion)
- Rotation around horizontal axis
- Rotation around vertical axis



→ The coordinate systems used in the measurement (M) and the treatment (T) have to coincide exactly!

Figure 2. Reproduction of the potential biases of decentration of the human eye. The centration has 5 degrees of freedom, allowing for horizontal and vertical shifts, rotation around the longitudinal axis, specifically cyclotorsion, and rotation around the horizontal and vertical axes.

ing. Previous studies have shown the advantage of active eye tracking in refractive surgery.⁶⁻¹⁰ There appear to be less significant aberrations with the tracker-treated patients.

Decentration zone

We measure decentration by obtaining the difference between the pre- and postoperative corneal topographic measurements. The ablation is surrounded by a region of approximately zero power.⁴ The decentration of the ablation is determined as a distance of the center of the flattened zone from the center of the pupil. We term an ablation grossly decentered if this decentration is more than 1 mm, although there is evidence that decentration, even as much as 100 microns, will significantly increase higher aberrations and the possibility of the symptoms described previously to affect the patients' visual quality.⁵

Ablation decentration can be avoided by precise calibration of the tracking device and frequent evaluations of the actual centration of the excimer laser to the tracking device. In routine clinical practice, we most commonly align axes X and Y and not axis Z. As a result of tilt in the Z axis, the ablation may be ellipsoidal rather than circular, for example.

Treatment technique

We treat decentered ablations with a preop evaluation using wavefront measurements and topographic measurements of the decentered ablation. We use the Allegretto flying spot laser (Wave-light, Erlagen, Germany; Lumenis the U.S. distributor). The basic characteris-

tics of this laser

We dilate the pupil with one drop of 1% tropicamide to attain at least a 7 mm pupil. The wavefront analyzer then projects onto a series of LED laser spots on the retina in a pre-determined scheme. Simultaneously, an infrared camera obtains data on the centration of this projection onto the retina based on the pupillary opening. The data for the quality of centration of this measurement are instantly recorded. Then, a small-aperture digital camera photographs the image produced by the LED diagnostic

measured by the Vector Vision 3000 device. The data for the quality of centration of this measurement are instantly recorded. Then, a small-aperture digital camera photographs the image produced by the LED diagnostic laser onto the retina, and these data are analyzed by the wavefront analyzer to calculate wavefront error. We use at least four well-centered, consistently patterned measurements in the X and Y axes. Once these data are determined to be qualitatively and quantitatively of equal quality (a subjective evaluation performed by the surgeon and the optometrist together in our center), the wavefront-guided treatment is calculated and transferred onto the excimer laser.

tics of this laser include a 0.9 mm Gaussian beam spot, operated at 200 Hz and directed by a 250 Hz sampling active eye tracker with a response time of 6 to 8 ms. The preoperative measurements include visual acuity, topography, OrbScan and wavefront measurements, and contrast sensitivity mea-

We lift the original flap for cases that are less than one year postop and create new flaps in eyes that are more than one-year postop. We use the Moria M2 with either a 110 or 130 micron setting; these settings create 130 and 150 micron flaps, respectively. We evaluate the thinnest corneal pachymetry very carefully to avoid excessive stromal thinning, and carefully evaluate the posterior corneal curvature with the OrbScan maps to have a qualitative idea of whether keratectasia may be starting in some patients.

The wavefront-guided enhancement is relatively standard. We use only one drop of Alcaine (proparacaine 0.5%, Allergan, Irvine, CA) as a topical anesthetic. We use the disposable and single-use Moria M2 head and disposable Visitec cannula for irrigation, and a disposable Weck Cell Microspear to reposition the flap following the procedure. We instill a drop of ofloxacin (Ocuflox, Allergan, Irvine, CA) mixed with preservative-free Acular (ketorolac tromethamine 0.5%, Allergan, Irvine, CA) as antibiotic prophylaxis several times during flap repositioning, and a drop of PredForte. We use PredForte for anti-inflammatory control, to delineate the flap gutter, and ascertain good centra-

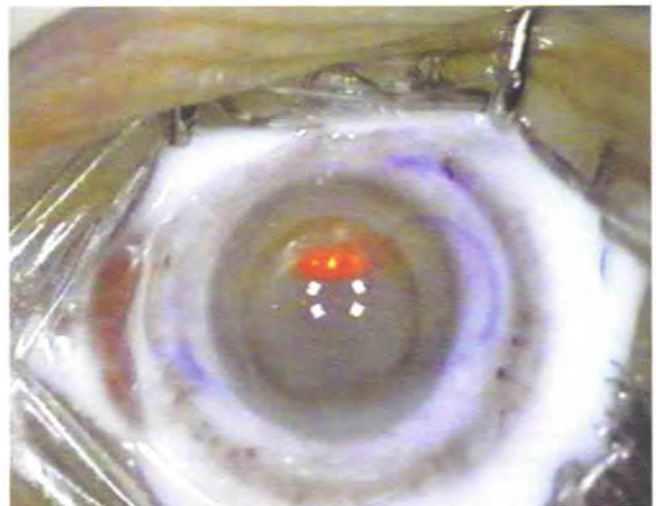


Figure 3. The picture depicts the surgeon's view of a superior hinged flap. Immediately following the administration of one drop of PredForte 1%, the flap borders are delineated by the dense suspension. The surgeon can evaluate for subtle decentration of the flap that would result in a wider gutter on one side than the other. By the same principle swelling or fluid entrapment within the superior part of the interface would make the inferior flap gutter wider. Any differences in the gutter width, either on the X or Y axis, even if the corneal markings are perfectly aligned, indicate a decentration of the flap, which requires repositioning.

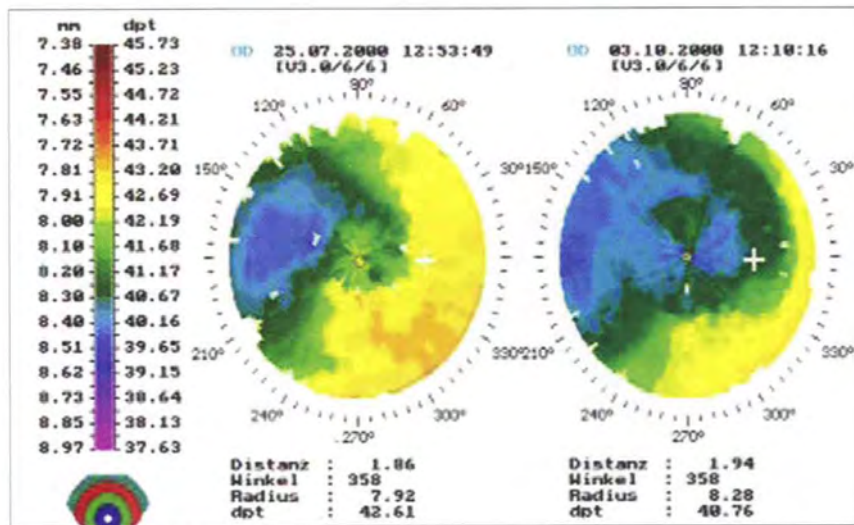


Figure 4. The image on the left represents preoperative corneal topography. The image on the right represents postoperative corneal topography.

tion of the repositioned flap. Any differences in the gutter width, either on the X or Y axis, even if the corneal markings are perfectly aligned, indicates a decentration of the flap, which requires repositioning. (Figure 3)

Results

The initial group of patients have subjectively improved symptoms including night driving and quality of night vision. All symptoms of monocular diplopia, ghosting and most of the glare subsided after treatment. (Figure 4, 5, 6)

With this method, we can obtain significant improvement, both in the signs and symptoms of decentered LASIK and PRK. Some of the obvious limitations are the condition of the cornea in these patients; specifically, the relative corneal thickness and our ability to perform an enhancement. Extreme decentrations, refractive errors, and higher order aberra-

tions may exceed the limits that this technology can measure precisely. Other methods to treat aberrated eyes are currently under study in the U.S.¹¹ There is also promising work being done in determining the specific Zernike polynomials in higher order aberrations are important functionally in humans. Better knowledge of the clinical correlation of these findings may help us create more effective customized enhancements.^{12,13} Further studies and clinical experience will enhance our understanding of most effective and safe methods to retreat aberrated eyes. **RRS**

Kanellopoulos is associate professor, New York University Medical School, New York, and medical director of the Laservision Eye Institute for Laser, Athens.

Mrochen is a researcher and clinician with the University of Zurich, Switzerland.

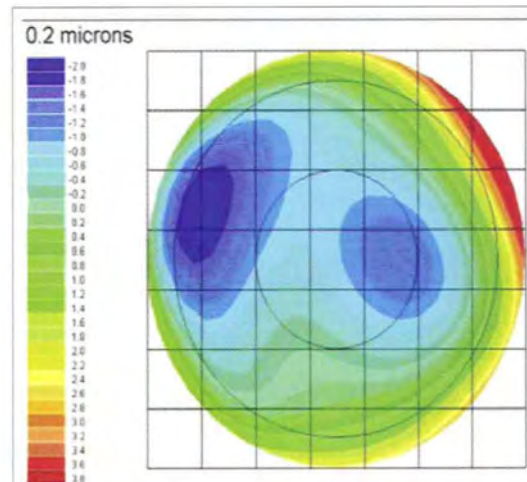


Figure 5. preop wavefront map.

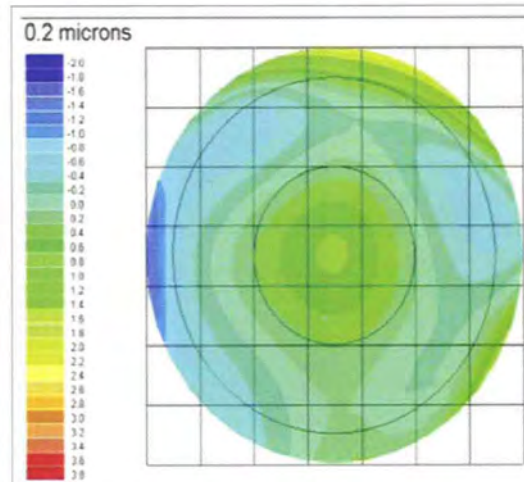


Figure 6. postop wavefront map.

Neither has a financial or consulting interest in the products mentioned. Contact Kanellopoulos at laservision@internet.gr and Mrochen at michael.mrochen@aug.usz.ch.

Figures 1, 2 and 3 are courtesy of A. John Kanellopoulos, MD. Figures 4, 5 and 6 are courtesy of Michael Mrochen, PhD.

REFERENCES:

- 1 Azar DT, Yeh PC. Corneal topographic evaluation of decentration in photorefractive keratectomy: Treatment displacement versus intraoperative drift. *Am J Ophthalmol* 1997; 124:312-20.
- 2 Mulhern MG, Foley-Nolan A, O'Keefe M, Condon PI. Topographical analysis of ablation centration after excimer laser photorefractive keratectomy and laser in situ keratomileusis for high myopia. *J Cataract Refract Surg* 1997;23:488-494.
- 3 Talamo JH, Wagoner MD, Lee SY. Management of ablation decentration following excimer photorefractive keratectomy. *Arch Ophthalmol* 1995;113:706-707.
- 4 Mrochen M, Krueger RR, Bueeler M, Seiler T. Aberration-sensing and wavefront-guided laser in situ keratomileusis management of decentered ablation. *J Refract Surg* 2002; 18:418-29.
- 5 Verdon W, Bullimore M, Maloney RK. Visual performance after photorefractive keratectomy: A prospective study. *Arch Ophthalmol* 1996;114:1465-1472.
- 6 Mrochen M, Eldeine MS, Kaemmerer M, et al. Improvement in photorefractive corneal laser surgery results using an active eye-tracking system. *J Cataract Refract Surg* 2001;27:1000-1006.
- 7 Taylor NM, Eikelboom RH, Van-Sarloos PP, et al. Determining the accuracy of an eye tracking system for laser refractive surgery. *J Refract Surg* 2000;16 (suppl):S643-S646.
- 8 Tsai YY, Lin JM. Ablation centration after active eye-tracker-assisted photorefractive keratectomy and laser in situ keratomileusis. *J Cataract Refract Surg* 2000; 26:28-34.
- 9 Pallikaris I, McDonald MB, Siganos D, Klonos G, et al. Tracker-assisted photorefractive keratectomy for myopia of -1 to -6 diopters. *J Refract Surg* 1996;12:240-247.
- 10 Gobbi PG, Carones F, Brancato R, et al. Automatic eye tracker for excimer laser photorefractive keratectomy. *J Refract Surg* 1995;11(suppl):S337-S342.
- 11 Tamayo G, Serrano M. Computerized topographic ablation using the Visx CAP method. In: MacRae S, Krueger R, Applegate R, eds. Customized corneal ablations: The quest for supervision. 1st ed. Thorofare, NJ: Slack;2001:281-289.
- 12 Applegate, RA, Ballentine C, Gross H, et al. Visual acuity as a function of Zernike Mode and Level of RMS Error, *Optom and Vis Sci*, in press.
- 13 Applegate, RA, Sarver EJ, Khemsara V. Are all aberrations Equal? *J Refract Surg* 2002. 18:S556-562.