

# Management of Corneal Ectasia After LASIK With Combined, Same-day, Topography-guided Partial Transepithelial PRK and Collagen Cross-linking: The Athens Protocol

Anastasios John Kanellopoulos, MD; Perry S. Binder, MS, MD

## ABSTRACT

**PURPOSE:** To evaluate a series of patients with corneal ectasia after LASIK that underwent the Athens Protocol: combined topography-guided photorefractive keratectomy (PRK) to reduce or eliminate induced myopia and astigmatism followed by sequential, same-day ultraviolet A (UVA) corneal collagen cross-linking (CXL).

**METHODS:** Thirty-two consecutive corneal ectasia cases underwent transepithelial PRK (WaveLight ALLEGRETTO) immediately followed by CXL (3 mW/cm<sup>2</sup>) for 30 minutes using 0.1% topical riboflavin sodium phosphate. Uncorrected distance visual acuity (UDVA), corrected distance visual acuity (CDVA), manifest refraction spherical equivalent, keratometry, central ultrasonic pachymetry, corneal tomography (Oculus Pentacam), and endothelial cell counts were analyzed. Mean follow-up was 27 months (range: 6 to 59 months).

**RESULTS:** Twenty-seven of 32 eyes had an improvement in UDVA and CDVA of 20/45 or better (2.25 logMAR) at last follow-up. Four eyes showed some topographic improvement but no improvement in CDVA. One of the treated eyes required a subsequent penetrating keratoplasty. Corneal haze grade 2 was present in 2 eyes.

**CONCLUSIONS:** Combined, same-day, topography-guided PRK and CXL appeared to offer tomographic stability, even after long-term follow-up. Only 2 of 32 eyes had corneal ectasia progression after the intervention. Seventeen of 32 eyes appeared to have improvement in UDVA and CDVA with follow-up >1.5 years. This technique may offer an alternative in the management of iatrogenic corneal ectasia. [*J Refract Surg.* 2011;27(5):323-331.] doi:10.3928/1081597X-20101105-01

**P**rogressive, asymmetrical corneal steepening associated with an increase in myopic and astigmatic refractive errors, combined with midperipheral and/or peripheral corneal thinning, represents a constellation of findings in ectatic corneal disorders, such as keratoconus and pellucid marginal degeneration. Asymmetry in presentation and unpredictability of progression associated with a myriad of abnormal topographic findings describe these entities. Similar findings following LASIK have been described as corneal ectasia.<sup>1-3</sup> Analysis of different series of eyes developing corneal ectasia after LASIK has suggested that certain preoperative and/or operative features may be associated with this adverse outcome of LASIK or photorefractive keratectomy (PRK).<sup>4</sup> The fact that corneal ectasia can occur in the absence of these features, or that it does not occur despite the presence of these features,<sup>5</sup> has confounded our understanding of this entity. Nevertheless, corneal ectasia after LASIK is a visually disabling complication with an ultimate surgical treatment of penetrating keratoplasty when spectacles or contact lenses can no longer provide patients with the quality of vision to permit activities of daily living.

Over the past 10 years, the use of topical riboflavin combined with ultraviolet A (UVA) irradiation to increase collagen cross-linking (CXL) has demonstrated the potential for retarding or eliminating the progression of keratoconus and corneal ectasia after LASIK. The application of CXL in corneal ectasia after LASIK has been reported previously.<sup>6</sup> Once

*From LaserVision.gr Institute, Athens, Greece (Kanellopoulos); New York University Medical College (Kanellopoulos) and Manhattan Eye, Ear and Throat Hospital (Kanellopoulos), New York, New York; and Gavin Herbert Eye Institute Department of Ophthalmology, University of California, Irvine, California (Binder).*

*The authors have no financial interest in the materials presented herein.*

*Presented as a paper at the American Society of Cataract and Refractive Surgery annual meeting; April 9-14, 2010; Boston, Massachusetts.*

*Correspondence: A. John Kanellopoulos, MD, LaserVision.gr Institute, 17 Tsocha St, Athens, 11521 Greece. Tel: 30 210 7472777; Fax: 30 210 7472789; E-mail: ajkmd@mac.com*

*Received: April 20, 2010; Accepted: October 13, 2010*

*Posted online: November 5, 2010*

the progression has stabilized, it is possible to treat the surface of the eye with customized PRK to normalize the corneal surface by reducing irregular astigmatism and potentially reducing the refractive error as well as providing improved visual outcomes in addition to stabilizing the disease process.<sup>7,8</sup> We have subsequently introduced the combined, same-day use of these two intervention modalities in the management of keratoconus.<sup>9-11</sup>

We present a series of patients with corneal ectasia after LASIK who have undergone combined, same-day, topography-guided PRK and subsequent UVA collagen CXL to achieve stabilization of corneal ectasia and enhance visual rehabilitation.

### PATIENTS AND METHODS

#### PATIENT SELECTION

Patients entered into this study were seen by one of the authors (A.J.K.) in his private practice, either through individual patient referral, referral from other eye care practitioners, or were his own patients. Once a diagnosis of corneal ectasia after LASIK was confirmed (see below), patients were presented with the options of contact lens fitting, intracorneal ring segment implantation, or, in advanced cases, penetrating keratoplasty. If these modalities did not serve the needs of the patient, he/she was then presented with the option of undergoing topography-guided PRK and UVA collagen CXL as a possible technique to prolong or prevent the need for penetrating keratoplasty. Patients provided verbal and written consent prior to undergoing the combined topography-guided PRK/CXL procedure.

A diagnosis of corneal ectasia was made when patients developed progressive corneal steepening associated with an increasing myopic and/or astigmatic refractive error 2 or more months after LASIK surgery. These findings were combined with increasing inferior corneal steepening and thinning based on videokeratography and ultrasound pachymetry. Preoperative LASIK clinical data and topography were requested from the referring physician or primary LASIK surgeon for analysis. Progression of the myopic refractive error with or without progression of the manifest astigmatism, decreasing uncorrected distance visual acuity (UDVA), loss of corrected distance visual acuity (CDVA), progressive inferior corneal steepening on topography, and/or decreasing inferior corneal thickness were findings in all cases.

#### CLINICAL EXAMINATION

Each patient underwent manifest refraction as well as measurement of UDVA and CDVA, which was re-

corded in a 20-foot lane using high-contrast Snellen visual acuity testing. Cycloplegic refractions were performed using 1% tropicamide solution (Alcon Laboratories Inc, Ft Worth, Texas). Slit-lamp microscopy confirmed the presence of a LASIK flap. Keratometry readings were obtained by videokeratography (Topolyzer; WaveLight AG, Erlangen, Germany) and/or manual keratometry (model 71-21-35; Bausch & Lomb, Rochester, New York). Pachymetry was performed using at least one of the following devices/instruments: Pentacam (Oculus Optikgeräte GmbH, Wetzlar, Germany), Orbscan II (Bausch & Lomb), or EchoScan US-1800 (NIDEK Co Ltd, Gamagori, Japan). Specular microscopy was performed using the Konan specular microscope (Konan Medical, Boston, Massachusetts). Topography was performed using the Orbscan II or Pentacam.

#### SURGICAL TECHNIQUE—THE ATHENS PROTOCOL

We have reported this technique in the management of keratoconus.<sup>9-11</sup>

*Step 1. The (Partial, Spherically Corrected) Topography-guided Transepithelial PRK Technique.* We devised this technique based on the proprietary WaveLight customized platform. As noted above, we previously described the use of the topography-guided platform with this device to normalize irregular corneas as well as corneal ectasia.

This customized excimer laser treatment is guided by topographic images and is different from wavefront-guided treatments. It received CE mark for clinical use in the European Union in 2003; however, it has yet to receive US Food and Drug Administration approval.

This proprietary software utilizes topographic data from the linked topography device (Topolyzer). By default, it permits the consideration of eight topographies (of predetermined threshold accuracy), averages the data and enables the surgeon to adjust the desired postoperative cornea asphericity (chosen as zero in all cases), provides the option of including tilt correction (no tilt was chosen in all cases), as well as the adjustment of sphere, cylinder, axis, and treatment zone (optical zone of 5.5 mm was chosen in all cases). The image of the planned surgery is generated by the laser software.

We used topography-guided PRK to normalize the cornea by reducing irregular astigmatism while treating part of the refractive error. To remove the minimum possible tissue, we decreased the effective optical zone diameter to 5.5 mm in all cases (compared to our usual treatment diameter of at least 6.5 mm in routine PRK and LASIK). We also planned ~70% treatment of cylinder and sphere (up to 70%) so as not to exceed 50  $\mu$ m in planned stromal removal. We chose the value of 50  $\mu$ m as the maximum ablation depth effected, based

on our experience of treating irregular corneas with this platform.<sup>7-10</sup>

Following the placement of an aspirating lid speculum (Rumex, St Petersburg, Florida), a 6.5-mm, 50- $\mu$ m phototherapeutic keratectomy (PTK) was performed to remove the corneal epithelium. Partial topography-guided PRK laser treatment was applied. A cellulose sponge soaked in mitomycin C (MMC) 0.02% solution was applied over the ablated tissue for 20 seconds followed by irrigation with 10 mL of chilled balanced salt solution.

*Step 2. Collagen CXL Procedure.* For the next 10 minutes, the proprietary 0.1% riboflavin sodium phosphate ophthalmic solution (Priavision, Menlo Park, California) was applied topically every 2 minutes. The solution appeared to “soak” into the corneal stroma rapidly, as it was centrally devoid of Bowman layer. Following the initial riboflavin administration, 4 diodes emitting UVA light of mean 370-nm wavelength (range: 365 to 375 nm) and 3 mW/cm<sup>2</sup> radiance at 2.5 cm were projected onto the surface of the cornea for 30 minutes (Keracure prototype device, Priavision). The Keracure device, which has a built-in beeper, alerts clinicians every 2 minutes during the 30-minute treatment to install the riboflavin solution in a timely fashion. A bandage contact lens was placed on the cornea at the completion of the combined procedures.

Postoperatively, topical ofloxacin (Ocuflox 0.3%; Allergan Inc, Irvine, California) was used four times a day for the first 10 days and prednisolone acetate 1% (Pred Forte, Allergan Inc) was used four times a day for 60 days. Protection from all natural light with sunglasses was encouraged, with administration of oral 1000 mg vitamin C daily for 60 days postoperative. The bandage contact lens was removed at or around day 5 following complete re-epithelialization.

## EVALUATION

The following evaluations were completed before and after both treatments: age, sex, UDVA, CDVA, refraction, keratometry, tomography, pachymetry, endothelial cell count, corneal haze on a scale of 0 to 4 (0=clear cornea, 1=mild haze, 2=moderate haze, 3=severe haze, and 4=reticular haze [obstructing iris anatomy]), and corneal ectasia stability as defined by stability in mean keratometry and tomography.

## CASE REPORTS

### CASE 1

A 39-year-old man had undergone LASIK in May 2004 at another institution. At that time, according to patient history, UDVA was counting fingers in both

eyes. Manifest refraction was  $-6.50 -0.50 \times 020$  (20/20) in the right eye and  $-6.00 -0.50 \times 165$  (20/20) in the left eye. Preoperative keratometry and corneal thickness readings were not available. No surgical data were available. The patient achieved UDVA of 20/20 in each eye, and reportedly plano refraction in both. In October 2005, he complained of progressively decreasing vision in both eyes. At that time, UDVA was 20/50 in the right eye and 20/40 in the left eye and he was told that “astigmatism was developing.”

The patient presented in March 2006, 26 months after LASIK, with a manifest refraction of  $+2.25 -1.75 \times 090$  (20/20) in the right eye and  $-1.25 -0.75 \times 010$  (20/20) in the left eye. Uncorrected distance visual acuity was 20/40 in the right eye and 20/30 in the left eye. Keratometry was 38.75@90/35.62@180 in the right eye and 40.65@05/39.55@95 in the left eye. Central corneal thickness (measured with Pentacam and ultrasound) was 495  $\mu$ m in the right eye and 505  $\mu$ m in the left eye, respectively. A diagnosis of bilateral corneal ectasia was made.

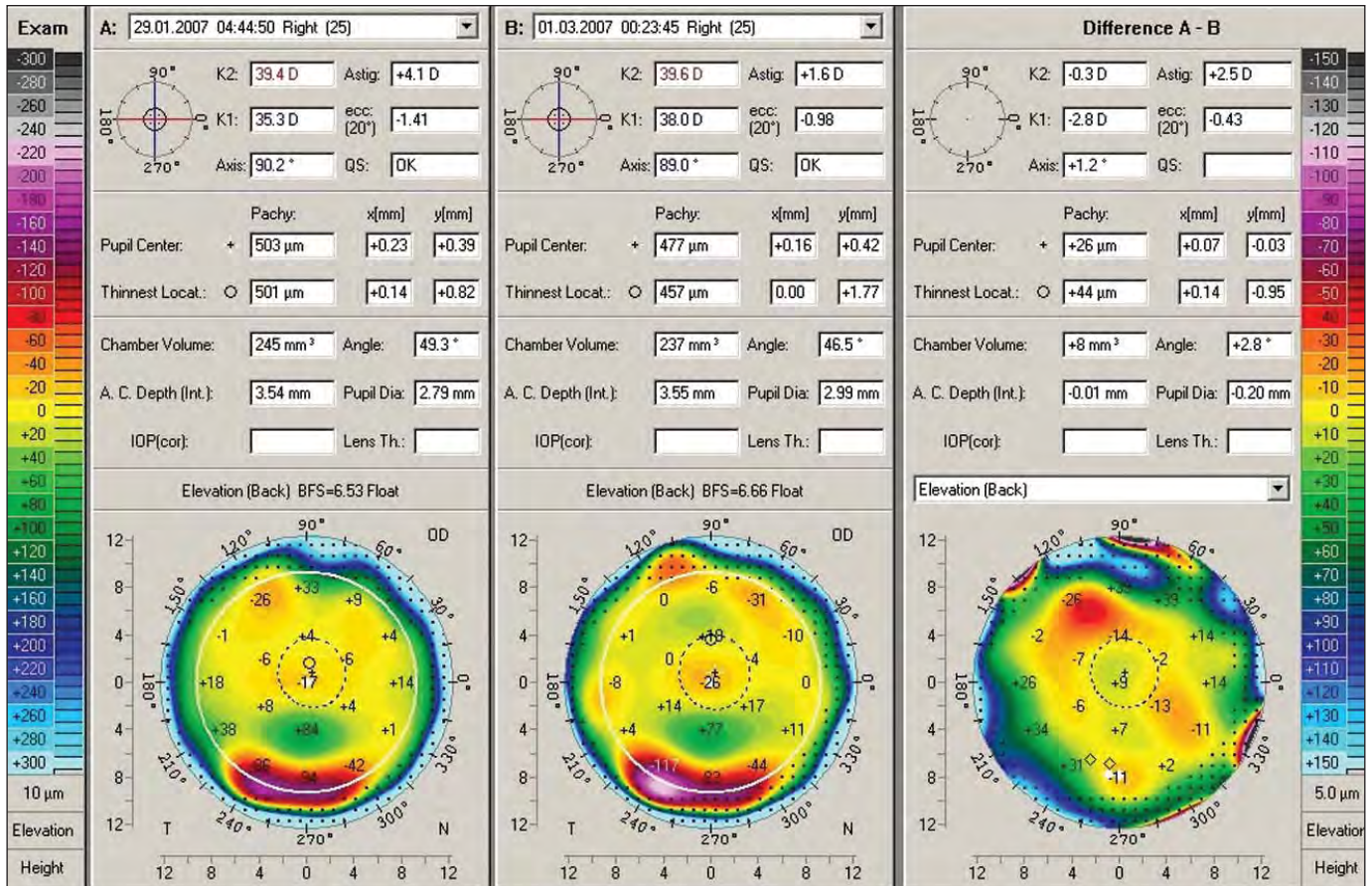
Because of the decrease in UDVA and the presence of corneal ectasia, the patient was informed of the risks, benefits, and alternatives of the combined topography-guided PRK/CXL technique. This procedure was performed on both eyes in January 2007, 32 months after LASIK. Based on the clinical manifest refraction of right ( $+2.25 -1.75 \times 90$  [20/20]) and left ( $-1.25 -0.50 \times 005$  [20/20]) eyes, the attempted correction was reduced to  $+1.75 -1.50 \times 90$  and  $-0.75 -0.50 \times 005$  for the right and left eyes, respectively. (The goal in the treatment was modified to anticipate the possible long-term flattening effect that CXL may have on these corneas.)

In February 2010, 37 months after topography-guided PRK/CXL, UDVA improved to 20/40 in the right eye and 20/20 in the left eye with a manifest refraction of  $-0.75$  (20/20) in the right eye and  $+0.25 -0.25 \times 95$  (20/20) in the left eye. Keratometry was 37.50@85/36.62@175 in the right eye and 37.75@79/37.87@169 in the left eye. Ultrasound pachymetry was 440  $\mu$ m and 414  $\mu$ m in the right and left eyes, respectively. Figure 1 demonstrates the pre- and postoperative topographies of the right eye as well as the difference map after treatment with the Athens Protocol.

### CASE 2

A 33-year-old woman reportedly had a manifest refraction of  $-4.00 -2.50 \times 90$  (20/20) in the right eye and  $-1.50 -2.00 \times 100$  (20/20) in the left eye. No other preoperative data were available. The patient had a history of eye rubbing.

Sometime in 2002, the patient underwent bilateral



**Figure 1.** Case 1. Clinical course of the right eye. Topography on the left shows marked central inferior corneal steepening consistent with corneal ectasia. The center image shows the final topography 2 years after initial LASIK, which is flatter and normalized. The image on the right demonstrates the comparison between preoperative and postoperative.

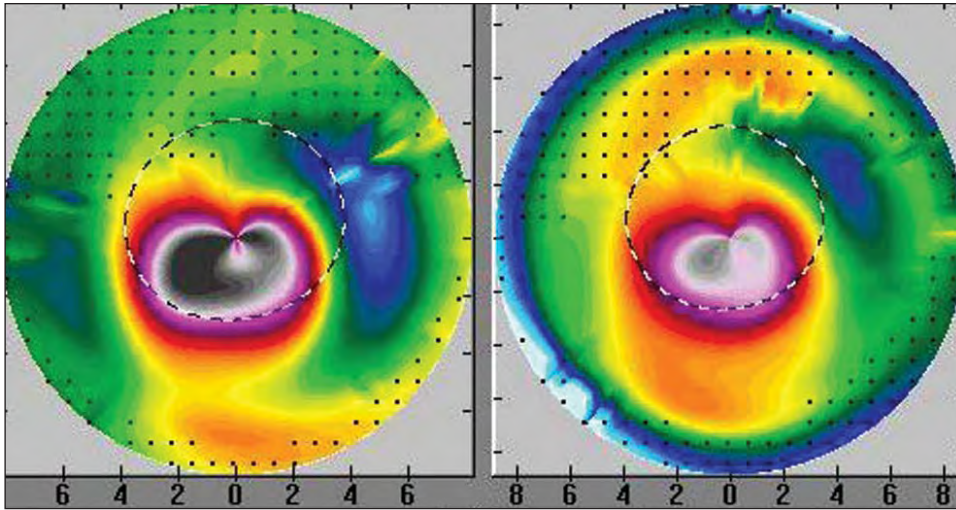
LASIK (the exact date is unknown and the surgical data were unavailable). Initially, the patient recovered excellent UDVA, but in December 2005, approximately 3 years postoperatively, she presented with slowly decreasing vision in both eyes. At that time, UDVA was 20/800 in each eye. Manifest refraction was  $-10.50 -6.00 \times 105$  (20/40) in the right eye and  $-7.75 -2.50 \times 110$  (20/30) in the left eye. Central corneal thickness measured by ultrasound was 395 μm in the right eye and 410 μm in the left eye. Keratometry was 52.87@103/46.12@13 in the right eye and 47.12@111/45.00@21 in the left eye. Corneal topography revealed bilateral corneal ectasia after LASIK, which was more pronounced in the right eye.

On December 19, 2005, >3 years after LASIK, the patient underwent topography-guided PRK/CXL in the right eye only, with no treatment in the left eye. At this time, manifest refraction was  $-10.50 -6.00 \times 105$  (20/30) in the right eye and  $-7.75 -4.50 \times 130$  (20/40) in the left eye. In June 2007, 18 months after topography-guided PRK/CXL, UDVA was 20/800 in each eye. Manifest refraction in the treated right eye had

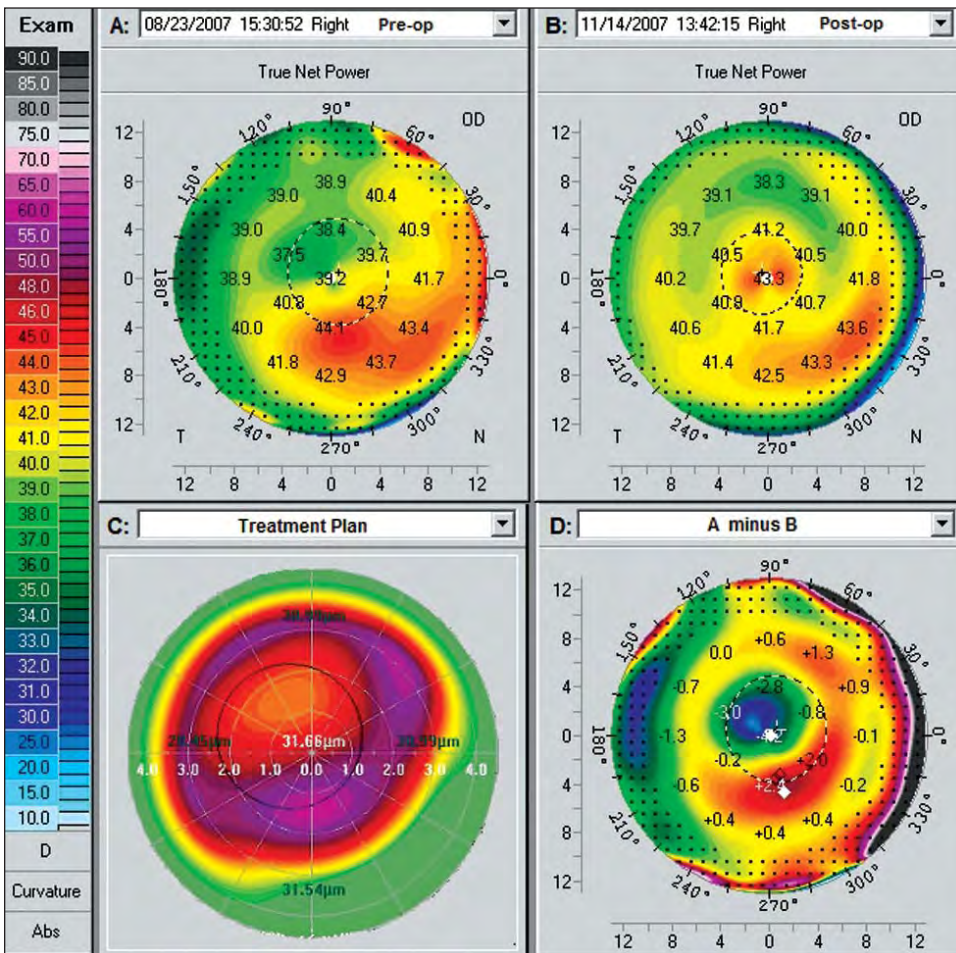
worsened to  $-12.00 -2.50 \times 100$  (20/40). Keratometry was 48.00@29/47.30@119 in the right eye and 47.87@20/46.20@110 in the left eye, and ultrasound pachymetry was 424 μm in the right eye and 388 μm in the left eye. Corneal topography revealed flattening in the difference map in the right eye (Fig 2). The patient was unhappy with this result and is currently uncomfortable with her anisometropia. She decided not to proceed with treatment in the fellow eye because she was unconvinced she had benefited from the topography-guided PRK/CXL procedure. She is currently wearing rigid gas permeable contact lenses in both eyes.

**CASE 3**

A 26-year-old male helicopter pilot underwent LASIK in both eyes in June 2004. No operative data were available. The only data available from the initial LASIK procedure was that he had “about”  $-3.00$  diopters (D) of myopia in both eyes prior to LASIK. Uncorrected distance visual acuity during the initial 2 years after LASIK was “good” but then deteriorated in his right eye. He was subsequently diagnosed with corneal



**Figure 2.** Case 2. Topography on the left shows marked inferior steepening before topography-guided PRK/CXL treatment. The topography on the right shows the same cornea 18 months after topography-guided PRK/CXL with marked flattening of the corneal ectasia and normalization of the cornea.



**Figure 3.** Case 3. Clinical course of the right eye. **A)** Topography 3 years after LASIK demonstrates irregular astigmatism and marked inferior corneal steepening. Uncorrected distance visual acuity was 20/40 and corrected distance visual acuity was 20/20 with refraction of  $+1.50 -2.00 \times 65$ . **B)** Topography 3 months after topography-guided PRK/CXL procedure demonstrates a flatter and normalized cornea. Uncorrected distance visual acuity was 20/15. **C)** Topographic reproduction of the topography-guided PRK treatment plan with the WaveLight platform. This platform plans to remove tissue in an irregular fashion to normalize the corneal ectasia seen in Figure 3A. **D)** Comparison map, derived from subtracting image B from A, represents the topographic difference in this case 3 months after the combined treatment. The paracentral flattening is self-explanatory, as the PRK and CXL have flattened the cone apex. The superior nasal arcuate flattening represents the actual part-hyperopic correction, which the topography-guided treatment has achieved, to accomplish steepening in the area central to this arc. Thus, the topography-guided treatment has normalized the ectatic cornea by flattening the cone apex and at the same time by “steepening” the remainder of the central cornea.

ectasia and was offered Intacs (Addition Technology Inc, Des Plaines, Illinois) or a corneal transplant.

He presented to our institution in September 2007, 3 years after LASIK. Uncorrected distance visual acuity was 20/40 in the right eye and 20/15 in the left eye. Manifest refraction was  $+1.50 -2.00 \times 65$  (20/20) in

the right eye and plano (20/15) in the left eye. Keratometry was  $41.62@65/43.62@155$  in the right eye and  $41.75/42.12@10$  in the left eye. Central ultrasound pachymetry was  $476 \mu\text{m}$  in the right eye and  $490 \mu\text{m}$  in the left eye.

On September 13, 2007, 39 months after LASIK,

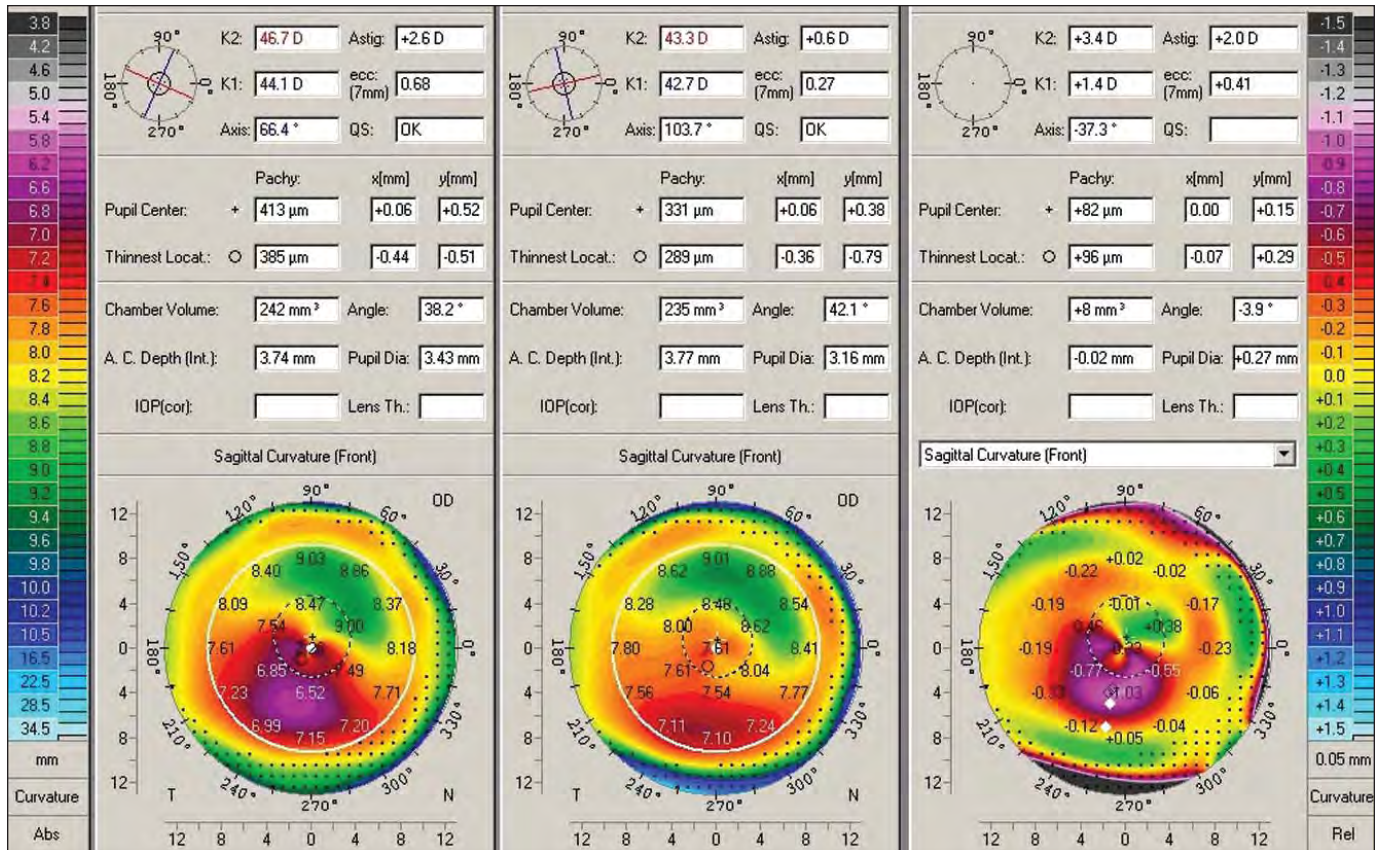


Figure 4. Case 4. Pentacam comparison of the right eye. The left column shows the data and topography before topography-guided PRK/CXL. The center column shows the postoperative data and topography. The right column shows the difference (pre- minus postoperative).

combined topography-guided PRK and immediate CXL was performed in the right eye for  $+0.50 -1.50 \times 60$ . The planned laser resection was 35 μm. Prior to treatment, manifest refraction was  $+1.50 -2.00 \times 65$ ; we reduced the attempted sphere and cylinder, anticipating a subsequent flattening effect of the sequential CXL procedure. Within 6 months, UDVA improved to 20/25 and 24 months later in September 2009, UDVA improved to 20/15 and the manifest refraction improved to plano  $-0.25 \times 05$  (20/10). Keratometry in the right eye was 43.00@97/43.25@07 and ultrasound pachymetry was 441 μm. The difference maps (Pentacam) before topography-guided PRK/CXL and 2 years postoperative are shown in Figure 3. At 3-year follow-up, UDVA remains at 20/10.

As a result of the improvement and stability in visual function, this patient has joined the United States Air Force as a fighter pilot and is currently serving in active duty.

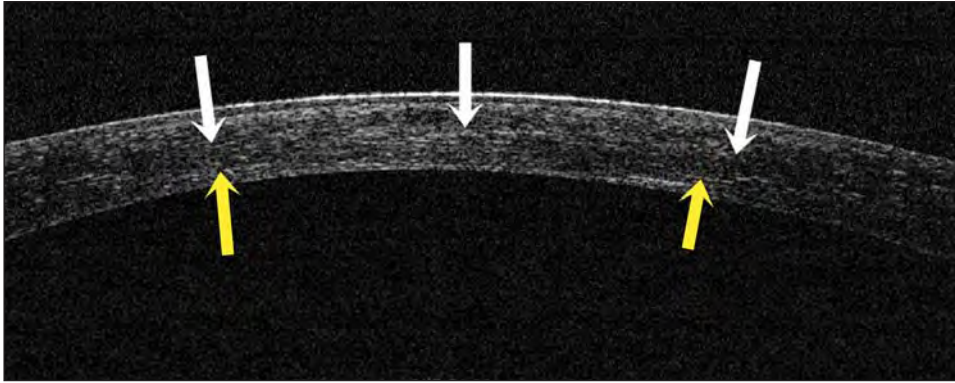
**CASE 4**

A 32-year-old woman underwent LASIK in both eyes in December 2006 for a refractive error of  $-3.75$  D in the right eye and  $-4.00$  D in the left eye. No other data

were available in regard to the surgery. Her vision was good for 2 years and then started to deteriorate. The treating surgeon made the diagnosis of corneal ectasia after LASIK in December 2008.

The patient presented to our institution in January 2009. Uncorrected distance visual acuity was 20/100 in the right eye and 20/20<sup>-2</sup> in the left eye. Corrected distance visual acuity was 20/30 with manifest refraction of  $-3.25 -3.25 \times 45$  in the right eye and 20/15 with  $+0.50 -1.25 \times 100$  in the left eye. Keratometry was 46.70@156/44.10@66 and 39.75@155/41.75@65 in the right and left eyes, respectively. Pachymetry readings were 419 μm and 460 μm in the right and left eyes, respectively. The diagnosis of corneal ectasia after LASIK was confirmed by Pentacam in the right eye (Fig 4, left image). The patient was contact lens-intolerant and opted to undergo topography-guided PRK/CXL despite the informed consent that the estimated residual corneal thickness would be 360 μm. This procedure was performed in February 2009 in the right eye.

The planned correction was  $-2.50 -2.50 \times 45$  after 6-mm diameter, 50-μm depth PTK. After ablation, 0.02% MMC in a moistened weck-cell sponge was used on the stroma for 20 seconds. In January 2010



**Figure 5.** Case 4. Optical coherence tomography of the central cornea in the right eye 11 months after topography-guided PRK/CXL. The hyper-reflectivity of the anterior 2/3 of the cornea suggests (as reported previously<sup>10</sup>) the CXL effect (yellow arrows). The hyper-reflective demarcation in the middle of the cornea (white arrows) suggests a thick LASIK flap calculated to  $>200\ \mu\text{m}$ .

(11 months following treatment), UDVA was 20/30, and CDVA was 20/20<sup>-1</sup> with manifest refraction of  $-0.50\ -0.75 \times 141$ . Keratometry was 43.30 and 42.70@103. Central corneal thickness was 330  $\mu\text{m}$ . The pre- and postoperative difference map is shown in Figure 4. Endothelial cell count was unchanged at 20 months (2600 cells/ $\text{mm}^2$  from 2650 cells/ $\text{mm}^2$  prior to application of the Athen's protocol).

Optical coherence tomography (OCT) of the central cornea in the right eye at 11 months postoperative shows hyper-reflectivity of the anterior 2/3 of the cornea (Fig 5) demonstrating the CXL effect, which we reported previously when applying similar treatment in cases of keratoconus.<sup>10,11</sup> The hyper-reflective demarcation in the middle of the cornea in this case suggests a thick LASIK flap calculated to  $>200\ \mu\text{m}$  by corneal OCT prior to application of the Athen's protocol.

#### SUMMARY OF ALL CASES

A total of 32 eyes in 22 patients with corneal ectasia occurring 1 to 4 years after LASIK were treated. Preoperative LASIK data were not available in most cases. In the 5 patients who had available data, no irregularity on topography or tomography was noted and no other factor of the LASIK procedure was evaluated to be high risk (eg, thick flap, residual stromal bed  $<250\ \mu\text{m}$ ). All patients had documented progression of inferior steepening in topography and/or tomography maps. Patient age ranged from 23 to 66 years (mean: 32 years) with gender divided (women:men=11:11). The mean measurements representing values after corneal ectasia were confirmed and preoperative to our technique were as follows. Mean sphere was  $-7.50\ \text{D}$  and mean preoperative astigmatism was  $-2.40\ \text{D}$  in the 32 eyes. Mean preoperative to the original LASIK central corneal thickness was  $\geq 525\ \mu\text{m}$  in 25 of 32 eyes. The original LASIK laser resection data were unavailable in 27 eyes, and flap thickness was assumed or calculated using corneal OCT (Optovue, Fremont, California). The mean residual stromal thickness was 285  $\mu\text{m}$  (range: 210 to 355  $\mu\text{m}$ ). Of all 32 ectasia cases, 15 were thought

to have resulted from thicker than planned flaps (mean residual stromal bed 230  $\mu\text{m}$ ), 10 showed signs of corneal irregularity on preoperative LASIK topography, and 7 had no recognizable risk factor for the development of corneal ectasia.

All topography-guided PRK procedures were planned to reduce corneal thickness by a maximum of 50  $\mu\text{m}$ , despite the existing refractive error, to avoid exacerbation of the ectasia. Most patients (19 patients, 25 eyes) complained of significant pain the first postoperative night whereas others reported minimal discomfort. Mean follow-up after the procedure was 27 months.

Uncorrected distance visual acuity improved in 27 eyes, was unchanged in 4 eyes, and worsened in 1 eye; it was 20/30 or better ( $+0.18\ \text{logMAR}$ ) in 11 of 32 eyes and 20/60 or worse ( $+0.47\ \text{logMAR}$ ) in 2 eyes. Corrected distance visual acuity was 20/40 or better ( $+0.30\ \text{logMAR}$ ) in 27 of 32 eyes and 20/25 or better ( $+0.10\ \text{logMAR}$ ) in 14 eyes.

Mean refractive error decreased by more than 2.50 D in 27 of 32 eyes, appeared to increase by 0.75 D in 3 eyes, and remained stable in 2 eyes. Mean final spherical equivalent refraction was  $-1.75\ \text{D}$ , indicating the reduction of cornea irregularity was the target and not emmetropia.

#### DISCUSSION

Topography-guided PRK flattens some of the cone apex (in a fashion similar to an eccentric partial myopic PRK) but simultaneously flattens an arcuate, broader area of the cornea away from the cone, usually in the superior nasal periphery; this ablation pattern (see Fig 3C) resembles part of a hyperopic treatment and thus will cause some amount of steepening or elevation adjacent to the cone, effectively normalizing the cornea. We have introduced this concept as an effective tissue-sparing ablation pattern in highly irregular corneas such as ectasia in keratoconus.<sup>12</sup> It is this core concept in the topography-guided PRK treatment that makes it, in our opinion, more therapeutic than refractive. We have reported<sup>7-10</sup> that in theory, the new "flatter" and

less irregular corneal shape may perform better biomechanically in eyes with corneal ectasia. Specifically, as the corneal apex becomes a flatter and “broader” cone (see Figs 3A and 3B), this may redistribute the biomechanical strain from the eye’s intraocular pressure and other external factors (eg, eye rubbing, blinking, etc). This effect may be further enhanced with additional collagen CXL strengthening.

Same-day simultaneous topography-guided PRK and CXL has several advantages: 1) the combination reduces the patient’s time away from work, 2) performing both procedures at the same time with topography-guided PRK appears to minimize the potential superficial stromal scarring resulting from topography-guided PRK (unpublished observations, December 2005), and 3) when topography-guided PRK is performed following the CXL procedure, some of the cross-linked anterior cornea is removed, minimizing the potential benefit of CXL (unpublished observations, December 2005). We believe it may be counterintuitive to remove the cross-linked tissue with topography-guided PRK at a later time, as we are potentially removing a beneficial layer of the stiffer, cross-linked cornea, which helps maintain the normalized corneal shape. Lastly, 4) by removing the Bowman layer with topography-guided PRK, this may facilitate riboflavin solution penetration in the corneal stroma and less “shielding” of UVA light in its passage through the cornea, resulting in more effective CXL.

Although a patient with corneal ectasia can have an improved visual result with the addition of the topography-guided PRK, completely removing significant refractive errors was not our goal. We have placed an arbitrary “ceiling” of 50  $\mu\text{m}$  to the amount of tissue that we safely removed centrally, anticipating that further thinning might destabilize the cornea’s biomechanical integrity, even following the “stiffening” effect of CXL.

It should be noted that the proprietary riboflavin solution used was a slightly hypotonic (340 mOsm) formulation, resulting in slight “swelling” of the cornea intraoperatively (during CXL). This restored the corneal thickness to approximately 400  $\mu\text{m}$  during CXL to protect the corneal endothelium; we did not encounter any corneal endothelial decompensation in any of the eyes studied herein despite treating cases with corneal thickness less than the theoretical limit of 400  $\mu\text{m}$ <sup>13</sup> prior to CXL (case 4).

In addition, the laser treatment was applied with caution, as the refractive effect of CXL (corneal flattening) had to be anticipated. For this reason, we elected to always attempt a significant undercorrection of both sphere and cylinder by at least 30%. At a later time, we hope to more accurately determine the new ablation rate of CXL stroma.

Simultaneous topography-guided PRK and CXL appears to be effective in the rehabilitation of corneal ectasia after LASIK. The reality of the efficacy of this treatment has been the reduction of penetrating keratoplasty cases performed for the indication of keratoconus and corneal ectasia after LASIK in our practice over the past 4 years. The same-day, simultaneous topography-guided PRK and CXL procedure was easy to perform, but in some cases, the central epithelial surface took up to 1 month to regularize and become lucent. It took from 1 to 4 weeks for us to detect stable changes in keratometry and topography, which seemed to match the visual and refractive changes.

The main goal for all refractive surgeons is to try to eliminate or at least significantly reduce the number of eyes developing corneal ectasia after PRK and LASIK. In some eyes, a preexisting condition that may lead to corneal ectasia with either PRK or LASIK may not be able to be detected, but by eliminating eyes with abnormal preoperative topography and leaving corneas with the maximum clinically acceptable residual stromal thickness, we will be able to reduce the number of eyes that develop corneal ectasia.

Our findings suggest potentially promising results with same-day, simultaneous topography-guided PRK and collagen CXL as a therapeutic intervention in highly irregular corneas with progressive corneal ectasia after LASIK. We have reported herein effective CXL treatment in cases with minimal corneal thickness <350  $\mu\text{m}$ . Our study demonstrates that we now have another means of improving the visual and refractive results of a devastating complication while avoiding or delaying penetrating keratoplasty.

#### AUTHOR CONTRIBUTIONS

*Study concept and design (A.J.K.); data collection (A.J.K., P.S.B.); analysis and interpretation of data (A.J.K., P.S.B.); drafting of the manuscript (A.J.K., P.S.B.); critical revision of the manuscript (A.J.K., P.S.B.); administrative, technical, or material support (A.J.K., P.S.B.); supervision (A.J.K.)*

#### REFERENCES

1. Binder PS. Ectasia after laser in situ keratomileusis. *J Cataract Refract Surg.* 2003;29(12):2419-2429.
2. Randleman JB, Russell B, Ward MA, Thompson KP, Stulting RD. Risk factors and prognosis for corneal ectasia after LASIK. *Ophthalmology.* 2003;110(2):267-275.
3. Tabbara K, Kotb A. Risk factors for corneal ectasia after LASIK. *Ophthalmology.* 2006;113(9):1618-1622.
4. Klein SR, Epstein RJ, Randleman JB, Stulting RD. Corneal ectasia after laser in situ keratomileusis in patients without apparent preoperative risk factors. *Cornea.* 2006;25(4):388-403.
5. Binder PS. Analysis of ectasia after laser in situ keratomileusis: risk factors. *J Cataract Refract Surg.* 2007;33(9):1530-1538.



6. Hafezi F, Kanellopoulos J, Wiltfang R, Seiler T. Corneal collagen crosslinking with riboflavin and ultraviolet A to treat induced keratectasia after laser in situ keratomileusis. *J Cataract Refract Surg.* 2007;33(12):2035-2040.
7. Kanellopoulos AJ. Post LASIK ectasia. *Ophthalmology.* 2007;114(6):1230.
8. Kanellopoulos A, Binder PS. Collagen cross-linking (CCL) with sequential topography-guided PRK: a temporizing alternative for keratoconus to penetrating keratoplasty. *Cornea.* 2007;26(7):891-895.
9. Ewald M, Kanellopoulos J. Limited topography-guided surface ablation (TGSA) followed by stabilization with collagen cross-linking with UV irradiation and riboflavin (UVACXL) for keratoconus (KC). *Invest Ophthalmol Vis Sci.* 2008;49:E-Abstract 4338.
10. Kanellopoulos AJ. Comparison of sequential vs same day simultaneous collagen cross-linking and topography-guided PRK for treatment of keratoconus. *J Refract Surg.* 2009;25(9):S812-S818.
11. Krueger RR, Kanellopoulos AJ. Stability of simultaneous topography-guided photorefractive keratectomy and riboflavin/UVA cross-linking for progressive keratoconus: case reports. *J Refract Surg.* 2010;26(10):S827-S832.
12. Kanellopoulos AJ. Managing highly distorted corneas with topography-guided treatment. In: *ISRS/AAO 2007 Subspecialty Day/Refractive Surgery Syllabus. Section II: Ablation Strategies.* San Francisco, CA: American Academy of Ophthalmology; 2007:13-15.
13. Spoerl E, Mrochen M, Sliney D, Trokel S, Seiler T. Safety of UVA-riboflavin cross-linking of the cornea. *Cornea.* 2007;26(4):385-389.