

Contralateral investigation of postoperative refractive surgery inflammation: Small-incision Lenticule Extraction vs LASIK.

ARVO 2016

Clinical & Research Eye Institute
Laser Vision
 Athens - Greece

Marianthi Stergiou, OD, George Asimellis PhD, and A. John Kanellopoulos MD
 The LaserVision.gr Clinical & Research Eye Institute, Athens, Greece & NYU Medical School, Dept of Ophthalmology, NY, NY

New York University
 School of Medicine


Purpose:

The purpose of this study was to comparative investigate potential impact of inflammation following myopic correction. The established current gold standard of femtosecond-assisted LASIK was compared to an all femtosecond laser Small Incision refractive Lenticule Extraction (SMILE). No study has investigated the potential differences between SMILE and LASIK from the stand-point of postoperative inflammation.

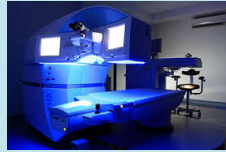Methods:

This is a contralateral, perspective study employing 30 consecutive myopic patients, in which one eye (group-A) was treated with the SMILE, while the other eye (group-B) with LASIK. The SMILE procedure employed the 500 kHz VisuMax® femtosecond laser (Carl Zeiss Meditec AG, Jena, Germany). The LASIK procedure employed the Alcon Refractive surgery platform (Alcon Surgical, Ft. Worth, TX) comprised of the FS200 femtosecond and the EX500 excimer laser

InflammaDry (Rapid Pathogen Screening, Inc., Sarasota, FL) is an in-office test that detects matrix metalloproteinase MMP-9, an inflammatory marker that is consistently elevated in the tears of patients with dry eye disease.




Using direct sampling microfiltration technology, InflammaDry identifies elevated levels of MMP-9 protein in tear fluid samples taken from the palpebral conjunctiva. Levels of MMP-9 were tested 1-month, 3-months and 6-months postoperatively, facilitated with the use of InflammaDry solution. Inclusion criteria: 18 years of age or older. Exclusion Criteria: Allergy to cornstarch or Darcon, Allergy to topical anesthetic or fluorescein dye.




The potential advantages of SMILE over LASIK other than the biomechanical aspect, include

- reduced dependence on environmental factors that may influence excimer stromal ablation, laser fluence variability and stromal hydration,
- reduced possibility for operating room airborne foreign-body interface contamination, and
- potentially reduced postoperative dry-eye symptoms* In terms of corneal sensation and dry eye outcomes, some studies have shown equivalence-if not superiority-of SMILE to LASIK.

How does the Epithelium look like in a Normal Eye?



How does the Epithelium look like in a Dry Eye?




New York University School of Medicine Prof. A. John Kanellopoulos, MD www.brilliantvision.com Eye Institute Laser Vision

Epithelial remodeling following myopic LASIK

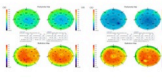
Epithelial thickness remodeling following LASIK has indicated a slight (average +3 µm) increase in epithelial thickness.

The increase was rather not-lenticular, but **more emphasized in the mid-periphery of 5 mm.**

The noted increase showed a **positive correlation to the amount of attempted myopic correction**: the larger the myopic correction, and thus, the stromal flattening, the larger the noted epithelial thickness increase.



Epithelial Remodeling following PRK



New York University School of Medicine Prof. A. John Kanellopoulos, MD www.brilliantvision.com Eye Institute Laser Vision

Results: positive for MMP-9

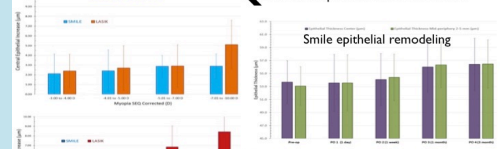
At 1 month: 1 smile vs. 17 LASIK of 25

At 3 months: 0 Smile vs. 8 LASIK of 25

These data document significant more inflammatory markers in LASIK possibly related to the much larger side cut flap incision and/or excimer laser ablation-stromal interaction. These data correlate well with our epithelium remodeling data shown in the separate study illustrated below

RESULTS:

← Central epithelium Smile vs. LASIK



← mid-periphery epithelium Smile vs. LASIK



Conclusions

Potential differences between SMILE and LASIK include increased inflammation levels postoperatively up to 6 months. This maybe related to the larger anterior corneal incision created in LASIK and may affect transient dry eye symptoms and their differences noted between the 2 procedures