

Surgical Visual Rehabilitation Techniques

Surgeons share their preferences for visual rehab after CXL.

BY JÉRÔME C. VRYGHEM, MD, PhD; EFEKAN COSKUNSEVEN, MD; ALBERT DAXER, MD, PhD;
A. JOHN KANELLOPOULOS, MD; AND RUDY M.M.A NUIJTS, MD, PhD

INTRODUCTION:

JÉRÔME C. VRYGHEM, MD, PhD

Therapeutic approaches to treating keratoconus have changed dramatically over recent years. Whereas in the past ectasia undoubtedly progressed to corneal deformation and visual deterioration, we can now rigidify, stabilize, and stop these symptoms using corneal collagen crosslinking (CXL) with UV-A and riboflavin. This treatment may also diminish the need for lamellar or penetrating keratoplasty (PK).

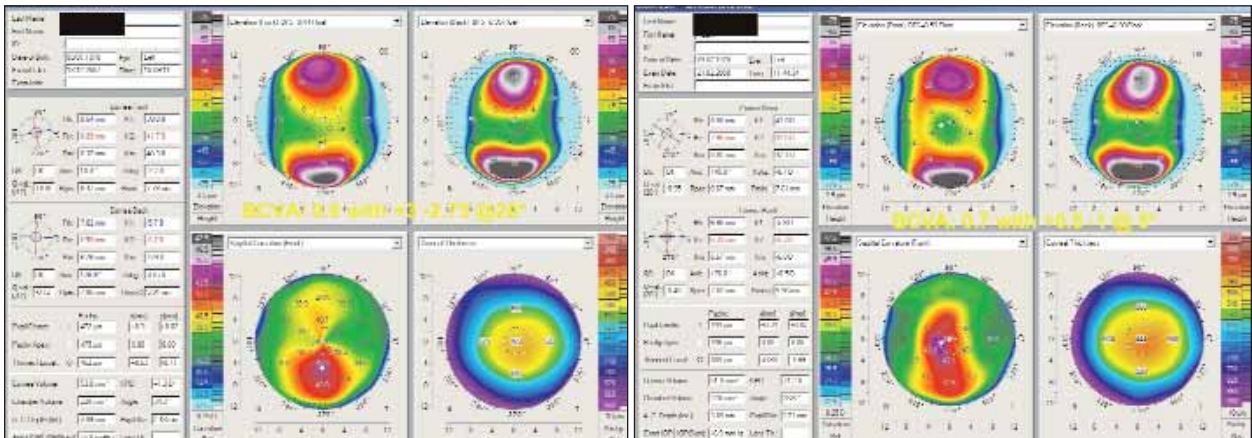
Ectatic progression varies from one patient to another. Although keratoconus has more chance to progress when the onset is early, its development tends to slow down after 30 years of age. Therefore, age may cause spontaneous crosslinking of the collagen fibers in the cornea.

Since December 2005, I have treated 98 eyes with CXL. I also participated in the European multicenter study led by Theo Seiler, MD, PhD, of Zurich, Switzerland. In my practice, two distinct groups have showed the most interest in CXL: younger patients with progressive keratoconus (56%) and patients older than 30 years of age with stabilized keratoconus and contact-

lens intolerance (27.5%). Other patients interested in CXL include those with post-LASIK ectasia (11%), combined myopia and forme fruste keratoconus (3.5%), and previous PK (2%).

Previously, intrastromal corneal ring segments (ICRS) were the only accepted option for surgical visual rehabilitation in noncrosslinked keratoconic corneas, mainly because of their reversibility. Topography-guided PRK was not a viable option because it further thinned the cornea, thus increasing the risk of destabilization. Recently, Nuijts and Budo found that phakic IOLs could also provide satisfactory results in patients with keratoconic corneas; however, phakic IOLs placed in an eye with an unstable cornea may eventually need to be explanted and replaced.

The recent prospect of using CXL to stabilize the keratoconic cornea and refraction promises maximized postoperative results. The aim is neither to correct the full refractive error nor obtain a perfect quality of vision; it is to create acceptable vision without systematically depending on glasses or contact lenses. Once stability has been demonstrated, new opportunities to rehabilitate vision of the



Figures 1 and 2. A case of CXL and topography-guided PRK. The patient's preoperative BCVA was 0.8; his refraction was +3.00 -2.75 X 20°. Postoperatively, his BCVA was 0.7; his refraction, +0.50 -1.00 X 5°.

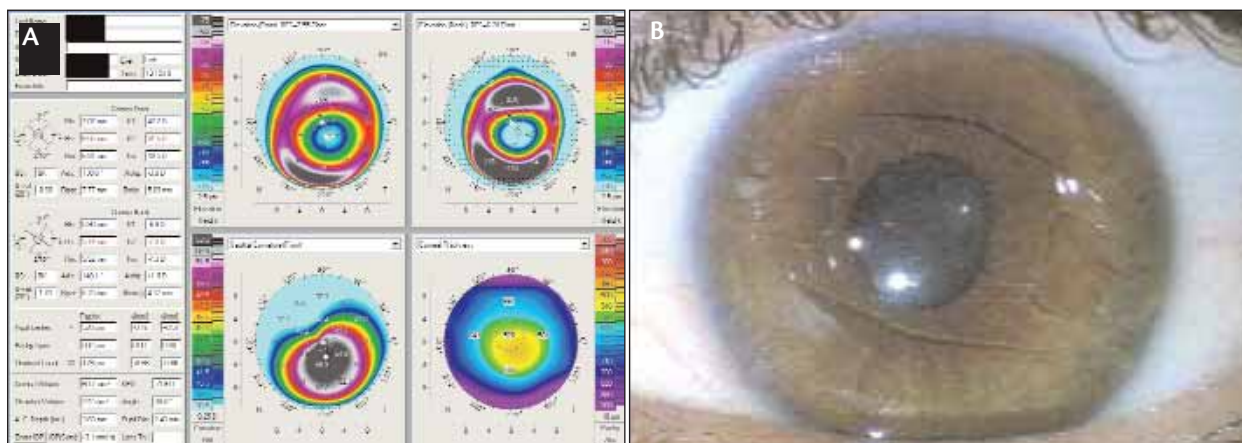


Figure 3. A case of CXL with a phakic IOL. (A) The patient's preoperative BCVA was 0.7; his refraction was $-7.00 -4.50 \times 165^\circ$. Postoperatively, his BCVA was 0.9; refraction was $-1.00 -0.50 \times 160^\circ$. (B) Postoperative view of the phakic IOL.

treated eye emerge, including topography-guided PRK (Figures 1 and 2) and phakic IOLs (Figure 3).

But which is the right procedure? We must rely on parameters like spherical equivalent, degree of astigmatism, and the thickness of the cornea to distinguish whether PRK or phakic IOL is the right choice. The only option for patients with high ametropia or astigmatism is the phakic IOL. For other patients, topography-guided PRK may be an option. In either circumstance, rehabilitation must not begin any sooner than 3 months after CXL if the patient is older than 30 years; if the patient is younger and has progressive keratoconus, at least 1 year recovery is required prior to rehabilitation.

During topography-guided PRK, 75% of the cylinder is removed as well as some or all of the sphere. The ablation never exceeds 50 μm , and the optical zone must be at least 5 mm. Mitomycin C 0.02% is applied for 30 seconds to avoid haze. Some surgeons, like A. John Kanellopoulos, MD, PhD, perform topography-guided PRK and CXL in the same session. The crosslinked surface layers are not ablated in the second stage (PRK). The advantage is that patients need only one surgery and experience visual improvement immediately; however, this approach is in the experimental stage.

Of the 98 eyes I have treated, surgical visual rehabilitation techniques were performed in 32. Of the 22 eyes with at least 6-month follow-up, 13 underwent topography-guided PRK and nine received the phakic IOL. Postoperative results of surgical visual rehabilitation after CXL are encouraging, although patient expectations must be realistic.

Both topography-guided PRK and phakic IOLs were effective, and patients gained several lines of UCVA; however, phakic IOLs were safer and patients gained lines in BCVA (Figure 4).

Sixty-nine percent of patients were satisfied with their

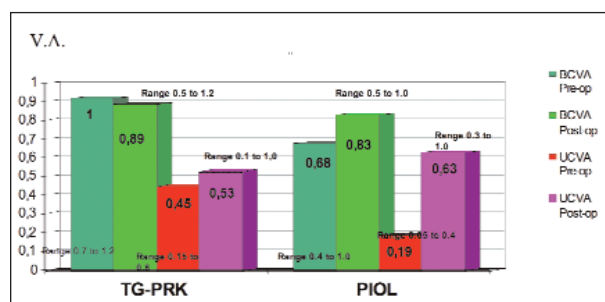


Figure 4. Patients gained lines in BCVA with the phakic IOL.

results after topography-guided PRK; however, frequently patients complained about the side effects, possibly because the treated eye stays in close competition with the nontreated eye. Patient satisfaction was higher (86%) in the phakic IOL group, mainly because the corrected ametropia (ie, myopia and astigmatism) was higher. Patients also experienced fewer side effects. In one case, additional fine-tuning was done with topography-guided PRK.

Surgical visual rehabilitation techniques applied to a stabilized keratoconic cornea after CXL offer new perspective for all keratoconus patients who still have a good BCVA (not lower than 0.3), cannot tolerate contact lenses, and have a cornea that is not deformed enough to necessitate keratoplasty. If visual rehabilitation has failed, lamellar or PK techniques still can improve the visual quality of the patient.

I invited Efehan Coskunseven, MD; Albert Daxer, MD, PhD; A. John Kanellopoulos, MD; and Rudy M.M.A Nuijts, MD, PhD, to comment on their experience with CXL and visual rehabilitation techniques. Participants were asked to answer the following questions: (1) What is your experience with CXL? What does your typical CXL procedure entail? (2) How long do you wait

(2) If the patient is already a contact lens user, he may begin to use his lenses 15 days after epithelialization. If a gas-permeable contact lens was previously used, new keratometry readings must be taken. Contact lens use may then begin between 1 and 3 months after reepithelialization. Otherwise, the gas-permeable contact lens may not fit the cornea properly.

(3) For visual rehabilitation additional to CXL, I prefer gas-permeable contact lenses or ICRS as treatment options. We first evaluate our keratoconic patients on the basis of BCVA. If BCVA is not reduced, keratoconus is observed only in topographic maps, and we are sure that there is no amblyopia or other pathology, we do not use visual rehabilitation techniques but continue to follow the patient closely. If the patient is younger than 30 years of age, I prefer follow-up every 3 months; however, follow-up every 6 months is sufficient for older patients.

I perform CXL only if there is proved progression. If progression is not evident, CXL should not be the first choice of treatment. If (1) there is no change in BCVA but the maximal keratometry reading changes 1.00 D or more at any point on the cornea or (2) corneal thickness decreases by 20 μm , keratoconic progression is evident. At this point, we should perform CXL. If BCVA is less than 20/20, it is measured with gas-permeable contact lenses. If it increases and if the patient is comfortable with the contact lens, we follow up every 3 months.

If the patient cannot use gas-permeable contact lenses, I recommend ICRS for visual rehabilitation. The BCVA achieved with gas-permeable contact lenses is the maximum visual acuity that we can obtain after implantation of ICRS, although I never promise that much visual acuity to the patient. First-month values are taken as a reference, and third-month values are compared with the reference values. I perform CXL if keratoconic progression is noticed.

In certain conditions, the combined treatment of ICRS implantation followed by CXL must be altered due to the patient's situation, including patients younger than 20 years old, those with corneal thickness less than 400 μm (with the risk of superficial migration of the segments), or if the patient will be unavailable for follow-up. In these conditions, we perform CXL treatment on the worse eye 1 month after ICRS implantation and follow with CXL on the second eye 1 month afterward (Figure 5).

Keratoconic progression after ICRS implantation is uncommon; however, it is hard to tell if progression stopped before or after treatment. I never promise the patients that ICRS will stop progression.

Advantages of ring segments include a more effective optical zone (5 mm), more arc options (90, 120, 160, 210), and a more consistent nomogram. My first experience using CXL after implantation of an ICRS was in a patient

with progressive keratoconus and corneal thickness of 400 μm . I had to remove the segments from one eye because of superficial migration. To avoid migration in the second eye (which was same thickness), I performed CXL. One year later, there is no problem with migration or melting in the second eye. After this experience, I performed ICRS implantation followed by CXL in 48 eyes of 43 patients with progressive keratoconus. Results were promising, with patients experiencing greater improvements in UCVA, BCVA, cylinder, and spherical equivalent compared with CXL followed by ICRS implantation. Additionally, simultaneous ICRS and CXL is unnecessary.

(4) CXL may make only minor changes to UCVA and BCVA; however, our study showed a mean increase of 0.5 lines in UCVA and BCVA in 27 eyes after CXL. The spherical equivalent, cylinder, and mean keratometry decreased by 1.39 D, 0.44 D, and 0.88 D, respectively ($P < .05$).

CXL should not be used if the central corneal thickness is less than 400 μm and if there is any accompanying corneal pathology or active ocular infection; it is also contraindicated in patients who are pregnant or breastfeeding.

ALBERT DAXER, MD, PhD

(1) We use CXL as a supplemental treatment to corneal intrastromal surgery (CISIS) in keratoconic patients. CISIS is performed by means of a particular microkeratome (PocketMaker; DiopTex GmbH, Linz, Austria) to create a closed corneal pocket in which a flexible full ring implant (MyoRing; DiopTex) is inserted via a small-incision tunnel.

(2) Usually, we perform CXL 2 months before CISIS; however, we recently performed them simultaneously, which also works well. I have developed a new technique for combining CISIS with CXL in one session, injecting the riboflavin into the corneal pocket created with the PocketMaker. This involves four steps: (1) creating a corneal pocket, (2) injecting riboflavin into the corneal pocket, (3) UV radiation of the cornea without corneal abrasion, and (4) implantation of the MyoRing into the corneal pocket. The advantage of this technique is that it avoids corneal abrasion. Therefore, patients do not experience pain and have a shorter recovery time.

(3) As a visual rehabilitation technique in keratoconus, we use only CISIS. In the case of advanced keratoconus or indication of progression, we combine it with CXL to get good long-term results.

(4) CXL hardens corneal tissue and amplifies the effects of the MyoRing in advanced keratoconus. The MyoRing can improve the central keratometry reading by more than 10.00 D. Additionally, we hope that CXL will freeze the corneal shape and stop progression.

I do not see any reason to avoid CXL before CISIS in these cases. In particular, patients with a corneal thickness

less than 400 μm obtain good results with this combination. We have even treated cases with corneal thickness as low as 350 μm . Injection of riboflavin into the corneal pocket or the use of hypotonic solutions before UV radiation guarantees that the 400- μm limit for CXL is not violated, even in such cases.

A. JOHN KANELLOPOULOS, MD

Following are my thoughts on visual rehabilitation after CXL. For a complete description of my technique, see my article, *Sequential Versus Simultaneous CXL and Topography-Guided PRK*, on page 44.

(1) My experience with CXL began in 2002, when I was inspired by one of Professor Seiler's presentations on experimental CXL. At my center in Athens, the Laservision.gr Institute, we commenced performing CXL in post-LASIK ectasia cases as the third European center, following Dresden and Zurich.

I was immediately impressed with the ability of CXL to stabilize the cornea, making visual rehabilitation possible in corneas that were otherwise destined for PK. My practice sees an exuberant number of young keratoconus patients from Greece and Cyprus, many of whom sooner or later were considered for PK if the cone exceeded reasonable rehabilitation with contact lenses and/or Intacs ICRS (Addition Technology, Inc., Des Plaines, Illinois).

I have since treated more than 900 cases, with 6-year follow-up in many patients. Our crosslinked cases are stable; however, visual rehabilitation is often a challenge when patients are contact-lens intolerant. This problem coincided with my early success with the topography-guided software from WaveLight (Erlangen, Germany). I had worked on several protocols in treating highly irregular corneas, and the thought of employing topography-guided PRK in some of these cases was promising. The concerns were whether these corneas would ablate like normal corneas and if it was safe to rehabilitate vision at the cost of further thinning the cornea. We introduced the novel approach of a therapeutic partial topography-guided PRK on cross-linked corneas following post-LASIK ectasia and primary keratoconus, and it has proven so far to be a great success. Some of these findings have been presented at meetings including the Association for Research in Vision and Ophthalmology (ARVO) and the American Academy of Ophthalmology (AAO)—and of course in *CRST* first.

(2) Following completion of numerous CXL cases followed by topography-guided PRK, I have switched to a combined simultaneous technique: I perform topography-guided PRK first (usually a partial PRK, mainly therapeutic

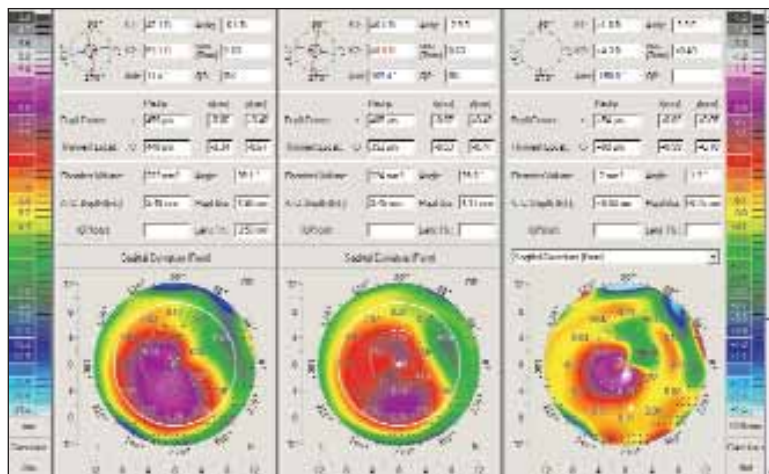


Figure 6. Before, after, and difference topographies.

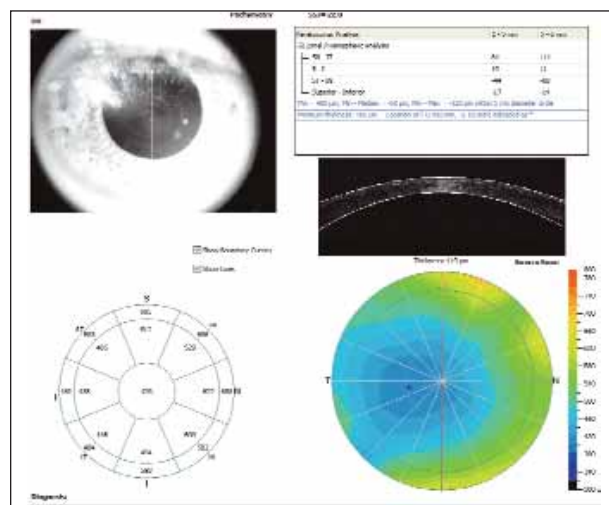


Figure 7. Cornea OCT pachymetry.

in design) followed by CXL immediately after.

Why bother with topography-guided PRK in the first place? Our long-term follow-up of CXL alone in keratoconus appears to halt ectasia progression; however, it also appears to leave the patient with puzzling visual rehabilitation when spectacles and contact lenses are ineffective or intolerable. In the patient population we have encountered over the years, the great majority will reach the point when CXL has successfully halted ectasia progression. The efficacy of topography-guided PRK has led to dramatic reduction of PK cases performed for keratoconus indications over the past 4 years.

(3) As I mentioned, I perform topography-guided PRK to normalize the cornea. I have also implanted phakic IOLs in cases with high residual myopia, specifically the Verisyse (Ophtec BV, Groningen, Netherlands).

(4) CXL prior to a phakic IOL will produce a more stable

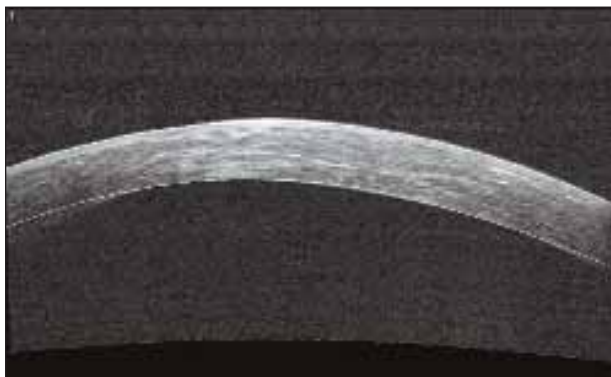

Figure 8. Corneal OCT cross section showing the depth of the CXL process at two-thirds to three-quarters of the central cornea.

ground for calculating the refractive error. In routine cases, I prefer to combine it with a partial-therapeutic approach, or topography-guided PRK, for several reasons. (1) I believe it synergizes the improvement of BCVA because the normalized cornea redistributes intraocular pressure to a broader area of the cone, not just the apex, adding to postoperative stability. (2) By removing Bowman's layer and some stroma, penetration of riboflavin is instant, facilitating rapid and deeper CXL. (3) By combining CXL and simultaneous therapeutic topography-guided PRK and avoiding the removal of crosslinked tissue with PRK later, the stability of CXL is preserved. (4) We have encountered much less haze when combining PRK and CXL versus performing PRK after CXL. This combination reduces the patient's time away from work. If the practitioner waits between procedures, keratocytes replenish and are activated by fibroblasts after the PRK. They may cause more scarring, even with the use of mitomycin. Performing both procedures at the same time with the PRK first tends to minimize any potential scarring from the PRK.

Figures 6 through 9 demonstrate a case in which topography-guided therapeutic PRK was combined with CXL for keratoconus. One year later, a Verisyse phakic IOL was implanted. At 1 year, the patient's UCVA improved to 20/25 from 20/400. BCVA improved to 20/20 from 20/70.

My personal experience with CXL has made me confident that it may develop as a viable adjunct to routine LASIK surgery. We have presented our experience with in-the-flap prophylactic CXL in femtosecond LASIK and are working on several protocols of UV-A fluence of 5, 7, and 15 mW/cm² to shorten the treatment time. Initial results look promising. CXL is a relatively new technique, and therefore ongoing and future experience will validate optimal UV-A light fluence, riboflavin concentration, and mode of administration (on the surface versus intracorneal). In my

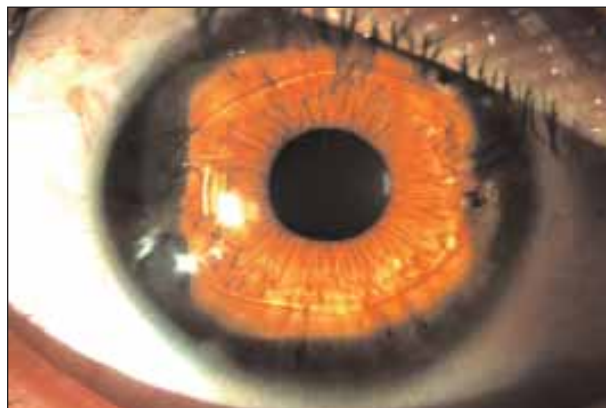


Figure 9. A Verisyse phakic IOL was implanted 1 year after combined PRK/CXL.

opinion, it will become the ultimate tool for customizing corneal biomechanical behavior.

RUDY M.M.A NUIJTS, MD, PhD

(1) We started using CXL as a treatment in progressive keratoconus relatively late in 2007. Our inclusion criteria include documented progression by corneal topography, BCVA greater than 0.4, pachymetry greater than 400 μ m, a central clear cornea, and age of at least 18 years old. We use the protocol as described by Wollensak et al,¹ consisting of corneal abrasion, application of 0.1% riboflavin for 30 minutes, and 30 minutes of irradiation with UV-A light using 3 mW/cm². A soft bandage contact lens is applied together with postoperative ofloxacin 0.3% and dexamethasone 0.1%. Typically, we can see a demarcation line 1 month postoperatively in the ocular coherence topography (OCT) image, dividing the treated and untreated cornea at an average depth of 313 μ m (Figure 10). We have seen a stabilization of BCVA and corneal topography 6 months postoperatively.

(2) Additional treatments for visual rehabilitation are indicated at least 3 months after CXL. However, patients usually return to contact-lens wear that, in the majority of cases, now consists of scleral contact lenses.

(3) Additional surgical treatments may consist of femtosecond laser-assisted implantation of corneal rings to centralize the area of steepness or of phakic IOL implantation to correct a large refractive error. The latter treatment is indicated only when there is a potential for good BCVA of at least 0.5.

In a series of 19 patients with stable keratoconus (stages one to two), Camille Budo, MD, and I have implanted Artisan (Ophtec BV, Groningen, Netherlands) toric phakic IOLs. Refractive astigmatism decreased from -4.57 ± 2.06 to -1.49 ± 1.31 and spherical equivalent from -8.15 ± 7.99 to -0.34 ± 1.00 (Figure 11). Eighty-four percent of patients had a BCVA of at

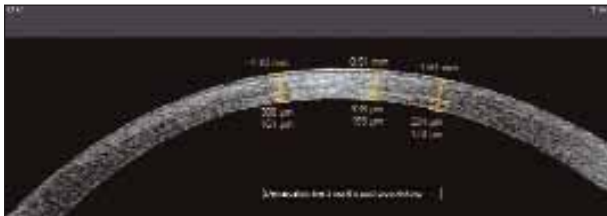


Figure 10. The demarcation line at 1 month, dividing the treated and untreated cornea at an average depth of 313 μm .

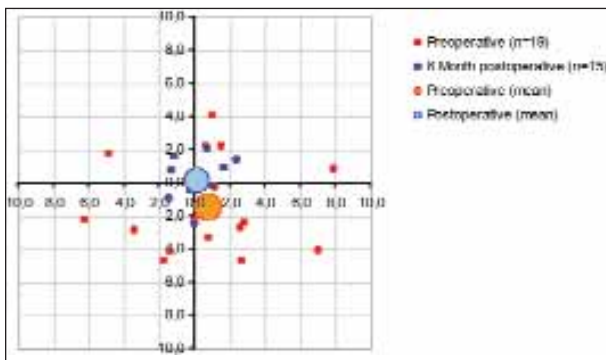


Figure 11. Refractive astigmatism decreased from -4.57 ± 2.06 to -1.49 ± 1.31 and spherical equivalent from -8.15 ± 7.99 to -0.34 ± 1.00 .

least 0.5, and 72% gained at least one line of BCVA (no patients lost more than two lines). In one case, we had to explant the phakic IOL because of progressive endothelial cell loss due to eye rubbing. We prefer phakic IOLs because of their reversibility; the lens can be explanted in the future when needed. In three cases, we have now applied a sequential treatment with CXL, femtosecond laser-assisted Intacs implantation, and toric Artisan implantation (Figure 12). Currently, we combine CXL with corneal ring implantation in cases with progressive keratoconus and contact-lens intolerance.

(4) CXL results in at least stabilization of the corneal shape. Therefore, I prefer to stabilize the cornea first in cases in which progression has been documented before further surgical rehabilitation. However, there may be cases of keratoconus in which progression does not occur on the short term, and here a more restricted treatment strategy is reasonable. Currently, we have not crosslinked corneas with a thickness less than 400 μm , and I await reports in the peer-reviewed literature to prove the safety of CXL in these cases. ■

Efekan Coskunseven, MD, practices at the Dunya Eye Hospital, Istanbul, Turkey. Dr. Coskunseven states that he has no financial interest in the products or companies mentioned. He may be reached at tel: +90 212 362 32 32; fax: +90 212

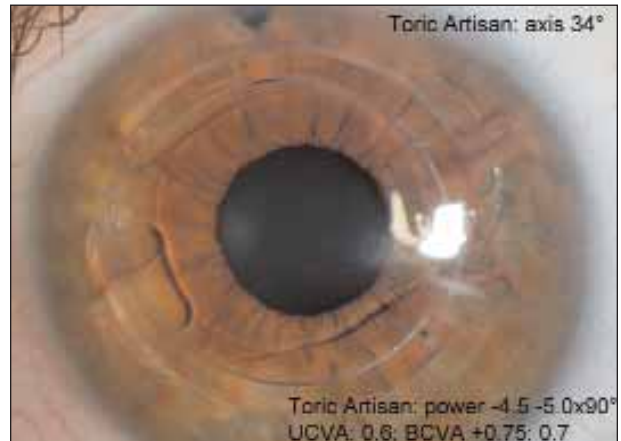

Figure 12. Sequential treatment with CXL, femtosecond laser-assisted Intacs implantation, and toric Artisan implantation.

275 05 80; e-mail: efekan.coskunseven@dunyagoz.com.

Albert Daxer, MD, PhD, is an Associate Professor of Ophthalmology, Department of Ophthalmology, Medical University in Innsbruck, Austria, and runs the Daxer Eye Center, Linz, Austria. Dr. Daxer did not provide financial disclosure information. He may be reached at e-mail: daxer@gutsehen.at.



A. John Kanellopoulos, MD, is Director of Laservision Eye Institute, in Athens, Greece. He is an Attending Surgeon in the Department of Ophthalmology at the Manhattan Eye, Ear, & Throat Hospital, in New York and Clinical Associate Professor of Ophthalmology at New York University Medical School. Dr. Kanellopoulos states that he has no financial interest in the products or companies mentioned. He is a member of the CRST Europe Editorial Board. Dr. Kanellopoulos may be reached at tel: +30 21 07 27 27 77; e-mail: ajk@laservision.gr.



Rudy M.M.A. Nuijts, MD, PhD, is an Associate Professor of Ophthalmology in the Department of Ophthalmology at Academic Hospital Maastricht, Netherlands. He states that he has no financial interest in the products or companies mentioned. He is a member of the CRST Europe Editorial Board. Dr. Nuijts may be reached at e-mail: rnu@compaqnet.nl.



Jérôme C. Vryghem, MD, is the Medical Director of Brussels Eye Doctors, Brussels, Belgium. Dr. Vryghem states that he has no financial interest in the products or companies mentioned. He is a member of the CRST Europe Editorial Board. Dr. Vryghem may be reached at e-mail: info@vryghem.be.



1. Wollensak G, Spoerl E, Seiler T. Riboflavin/ultraviolet-a-induced collagen crosslinking for the treatment of keratoconus. *Am J Ophthalmol* 2003;135(5):620-627.